

Treatment of bilateral cleft lip and palate long term results and future perspectives

Gerhard Koendert Pieter Bittermann

ISBN: 978-94-6423-233-2

Cover design & lay-out: Wendy Schoneveld || www.wenziD.nl

Printed by: ProefschriftMaken || ProefschriftMaken.nl

The research described in this thesis was performed at Mondziekten, Kaak- en Aangezichtschirurgie, Wilhelmina Kinderziekenhuis UMC Utrecht

Financial support by Utrechtse Stichting tot bevordering der mondziekten, kaak- en aangezichtschirurgie and Dirk en Lietje Bittermann

© Gerhard Koendert Pieter Bittermann, 2021

All rights reserved. No part of this thesis may be reproduced, stored or transmitted in any form or by any means without prior permission of the author, or the copyright-owning journals for previously published chapters.

Treatment of bilateral cleft lip and palate long term results and future perspectives

**Behandeling van de bilaterale schisis
Langetermijnresultaten en toekomstperspectieven**
(met een samenvatting in het Nederlands)

Proefschrift

ter verkrijging van de graad van doctor aan de
Universiteit Utrecht
op gezag van de
rector magnificus, prof.dr. H.R.B.M. Kummeling,
ingevolge het besluit van het college voor promoties
in het openbaar te verdedigen op

dinsdag 1 juni 2021 des ochtends te 10.15 uur

door

Gerhard Koendert Pieter Bittermann

geboren op 19 augustus 1987
te Giessenlanden

Promotor

Prof. dr. A.J.W.P. Rosenberg

Copromotoren

Dr. R.J.J. van Es

Dr. A.P. de Ruiter

CONTENTS

CHAPTER 1	Introduction	7
CHAPTER 2	Management of the premaxilla in the treatment of bilateral cleft of lip and palate: what can the literature tell us?	17
CHAPTER 3	Incidence of complications in secondary alveolar bone grafting of bilateral clefts with premaxillary osteotomy: a retrospective cohort study	39
CHAPTER 4	Midfacial growth and dental arch relationships in bilateral cleft palate following secondary alveolar bone grafting and orthodontic intervention: Factors predicting a Le Fort I osteotomy at age 18	57
CHAPTER 5	Retrospective analysis of clinical outcomes in bilateral cleft lip and palate patients after secondary alveolar bone grafting and premaxilla osteotomy using a new Dento-Maxillary Scoring System	77
CHAPTER 6	Taking the endochondral route to craniomaxillofacial bone regeneration: A logical approach?	95
CHAPTER 7	General discussion	115
CHAPTER 8	Summary	127
CHAPTER 9	Nederlandse samenvatting	134
	List of publications	139
	Dankwoord	142
	Curriculum Vitae	146



CHAPTER 1

Introduction

INCIDENCE OF BILATERAL CLEFT LIP

In the Netherlands, congenital disorders are present in 2.2% of all newborn children [1]. Amongst these, cleft lip and palate (CLP) is one of the most common birth defects. The incidence of all types of CLP in the Netherlands has slightly decreased in recent years: from 0.20% of all newborns in 2014 to 0.19% in 2015 and 0.18% in 2016. In Europe, the incidence of CLP ranges from 0.09% to 0.27% in all alive or still-born children. The incidence of alive born children with bilateral cleft lip and palate (BCLP) in the Netherlands was 0.025% of all new-borns in 2014, 0.016% in 2015 and 0.019% in 2016, and amounts about 10% of all CLP patients [2, 3, 4]. As in CLP patients in general, the incidence of BCLP in boys is twice the incidence in girls [5,6]. The reason for the higher incidence in boys is unknown.

DIAGNOSIS OF CLEFT LIP

In the Netherlands CLP is in most cases diagnosed at about 20 weeks of pregnancy, when the face of the fetus is screened as standard part of a prenatal ultrasound (US) examination. In 2011 95% of the pregnant women in the Netherlands opted for this routine US examination at 18 to 22 weeks of gestation. The sensitivity of the US test for cleft lip with or without cleft palate is increasing, due to technical innovation and training of specialized sonographers. Early this century a detection rate of 23% was reported Russel et al. 2002 and in 2011 a detection rate of 88% [7]. If the prenatal screening reveals a suspicion of an anomaly, the *gravid*a is referred to a regional center for further tests and counselling. It cannot be taken for granted that parents will accept a child with CLP [8]. In a number of cases parents decide to end the pregnancy. The number of terminated pregnancies in case of CLP is currently unknown. Between 2005 and 2008 in the Utrecht region, which has about 20.000 pregnancy's annually, 78 cases of CLP were diagnosed with ultrasound. Of these, 45 cases were isolated cases of CLP and 33 had associated anomalies visible on US or detected by additional tests. Three (7%) of the isolated cases of CLP and twenty-two (67%) of the associated cases, mostly trisomies, were terminated by abortion [9].

COUNSELING BY A MULTIDISCIPLINARY TEAM

Bilateral cleft lip and palate patients are preferably treated in a tertiary center, such as our hospital, the Wilhelmina Children's Hospital of the University Medical Center Utrecht (WCH UMC Utrecht). We treat all CLP patients, including BCLP, in a multidisciplinary team of specialists in the fields of obstetrics, plastic and maxillofacial surgery, orthodontics, audiology, pediatric otolaryngology, speech pathology, occupational/feeding therapy, genetics and psychiatry. Ideally, treatment starts before birth. The parents are introduced to the cleft team, who explain what to expect in the first year with a baby with (B)CLP.

Counseling of the parents by the psychologist is an essential part of these consultations. A proper pre-operative counseling helps parents accepting a child with a birth defect. The parents are better prepared and counseling may help in establishing a good parent-child relationship. Counseling by members of the CLP team offers many practical tips for the period directly after birth. One of the first problems concerns feeding of the child. Parents are made aware of these feeding problems and taught feeding with a longer teat and smaller amounts of milk. Up to the age of 18, children with (B)LCP and their parents require intensive training and advice in the fields of dietetics, speech therapy, dental hygiene, orthodontics, psycho-social development, hearing disorders and cosmetic anomalies [10].

OVERVIEW OF SURGICAL CORRECTIONS

The maxillofacial surgeon is a key member of the cleft team, who coordinates growth disturbances together with the orthodontist, and executes various surgical procedures in and around the mouth. During the first year of the child's life two or three surgical procedures are scheduled. The lip is closed in one operation if possible. In case of wide clefts and a protruding premaxilla closure of the lip is performed in two stages, where the first operation is a lip adhesion. When the child is six to twelve months of age the soft palate is closed. Currently, in our hospital delayed closure of the hard palate is favored, meaning that closure is postponed until the child is over 3 years old [11]. Between 9 to 12 years of age, depending on the development of a lateral incisor or canine, an early secondary alveolar bone grafting is executed on both clefts. In BCLP patients this grafting is combined preferably with an osteotomy of the premaxilla in one surgical procedure [12]. Secondary corrections, if needed, are planned after the age of 18 years. Secondary corrections are, for example, surgical advancement of the maxilla by a Le Fort I osteotomy, placement of dental implants in order to fill out diastemas and secondary nose and lip corrections. The cleft team of WCH UMC Utrecht aims for a treatment outcome that encompasses several aspects of the child's well-being: an uninterrupted maxillary dental arch over the grafted area, no fistulas, proper speech, good functioning of the nose, good hearing and harmonically balanced symmetrical facial esthetics with minimal cleft stigmata.

LIP CLOSURE IN BILATERAL CLEFT PATIENTS

An important aspect of the BCLP patient is that the alveolar clefts cause the premaxilla to be mobile as it is only apically fixed to the septal and vomerine bone. This may cause abnormalities in the position of the premaxilla. The premaxilla is often protruded due to the lack of sphincter function of the *orbicularis oris* muscle. Sometimes, the whole segment is rotated anteriorly resulting in a functional and cosmetic disorder. Over time, many types of treatment have been developed that aim at changing the position of the premaxilla. In

early ages of bilateral cleft lip surgery, surgeons sometimes even resected a severely protruded premaxilla [13]. Later, osteotomy of the premaxilla (setback osteotomy) was carried out in an early phase treatment, during or before lip closure. As this proved to have a detrimental effect on growth of the maxilla the procedure was abandoned [14, 15]. To correct the position of the severely protruded premaxilla, a lip adhesion is the preferred first surgical step. In a lip adhesion the ventral part of the nasal floor and the cranial part of the lip are closed [16, 17]. The adhesion directs the premaxilla within several weeks in a less protruded position, which facilitates the second step: closure of the lip. The closure of the lip will be executed with less tension and is planned about three months later [17, 18]. Several methods have been described in literature. The straight Veau closure is probably the most practiced technique in BCLP patients. At WCH/UMC Utrecht closure of the lip is done according to a modified Millard or Tennison [18, 19, 20].

CLOSURE OF THE VELUM AND THE HARD PALATE

Before speech starts at one year of age, closure of the soft palate is carried out using opposing Z-plasty and union of the M. levator veli palatini, according to the Sommerlad method, at 1 year of age [21, 22]. At a later age, the hard palate is closed according to von Langenbeck and 2 vomer flaps. If speech develops insufficiently, a pharyngoplasty according to a modified Honig technique is performed or a buccal sandwich flap [23, 24].

CLOSURE OF THE ALVEOLAR CLEFT

The closure of the alveolar cleft involves an autologous bone graft. Secondary alveolar bone grafting (SABG) means closure of the alveolar cleft after the soft palate was closed earlier. Different opinions exist concerning the optimal timing and technique for closure of the alveolar clefts in BLCP patients. Especially handling of the position of the premaxilla in combination with alveolar bone grafting is technically difficult. After labial and palatal surgery, the premaxilla may be displaced and demonstrate insufficient vertical growth and can be retruded, twisted or caudally positioned. Teeth in the premaxilla may be in an aberrant position, hypoplastic or even absent. Two strategies exist concerning repositioning of the premaxilla: orthodontic alignment in the dental arch, and surgical repositioning. The best timing of the premaxillary osteotomy in combination with closure of the alveolar cleft by a bone transplant is still debated in literature. The blood circulation of the premaxilla is entirely dependent on the connection of the mucosa to the nasal septum and vomerine bone. Therefore, an osteotomy of the premaxilla carries the risk of avascular necrosis. The osteotomy of the premaxilla is done to correct the position of the premaxilla, to close the nasal floor watertight and to have enough oral mucosa to cover the transplanted bone in the alveolar defect. [25, 26].

The alveolar cleft is in fact a critical size bone defect. This means that it is an orthotopic defect that will not heal without intervention [27]. The alveolar cleft needs to be grafted with bone to be able to close the defect. The current gold standard of treatment for critical size calvarial and facial bone defects is autologous bone grafting using either free or vascularized bone grafts from the calvarium, chin, rib, scapula, iliac crest, or fibula. In the UMC Utrecht new methods for bone grafting are being developed. One successful new method is the use of the bone substitute Bèta TriCalciumPhosphate (Bèta-TCP) in unilateral cleft lip and palate patients[28, 29].

BILATERAL CLEFT LIP AND PALATE IN THE WILHELMINA CHILDREN'S HOSPITAL (WHC) OF THE UNIVERSITY MEDICAL CENTER UTRECHT

Between 2004 and 2014 all patients with BLCP were treated according to a fixed treatment protocol. This resulted in a group of 69 well-documented patients. This group is of significant size when compared to other available studies on this topic, that vary between 5 and 50 included patients [30, 31, 32, 33].

In the WCH UMC Utrecht, secondary alveolar bone grafting and premaxilla osteotomy (SABG+PO) is planned between 8 and 12 years of age and executed by maxillofacial surgeons. In BCLP patients SABG is combined with a premaxilla osteotomy. The graft is harvested from the symphyseal area of the mandible or from the iliac crest [34]. SABG+PO is carried out to restore the contour of the alveolar ridge. The premaxilla is osteotomised to have good exposure of the nasal mucosa for watertight closure and to reposition it in a favorable anatomic position. Therefore, secondary alveolar bone grafting is combined with an osteotomy of the premaxilla. Timing is dependent on the development of the root of the cuspid or lateral incisor if present in the lateral segment. Surgery is planned if the root of the cuspid is formed halfway to 2-thirds.

After this procedure, the premaxilla is stabilized by a vomerine bone ligature and individualized metal splint. After a period of 6 to 8 weeks postoperatively, orthodontic treatment is started or continued to move lateral teeth into the newly grafted bone or to assist eruption of the canine. Orthodontic correctly positioning of the teeth in/into the grafted alveolar cleft is important to stabilize the volume of the bone graft [35].

AIMS OF THE STUDY

The overall aim of the studies in this thesis was to evaluate the results and outcomes of the WHC UMC treatment protocol for alveolar bone grafting in BCLP patients. Also the future of bone grafting procedures using regenerative medicine is reviewed.

Research questions

Is timing of secondary alveolar bone grafting together with premaxilla osteotomy between 8-12 year of age using the developmental stage of the root of the canine as a guidance for timing, a good strategy?

In bilateral cleft lip and palate patient's growth might not only be disturbed due to surgery. Are other factors involved?

Are there parameters in the BAURU Yardstick and in the cephalometric analysis for bilateral cleft lip and palate patients that can be used to predict midfacial growth of the bilateral cleft lip palate patients at an age between 8 and 12 years?

Does the Utrecht BCLP treatment protocol result in interconnected natural teeth over the grafted area without residual fistulas and without prosthetic reconstructive dental implants, or dental appliances at the age of 18 years?

Overview

Chapter two: the literature is reviewed to compare current treatment protocols for alveolar bone grafting with the WCH UMC Utrecht treatment protocol. A consensus of best practice based on literature is formulated.

Chapter three: The current treatment protocol Secondary Alveolar Bone Grafting and Premaxilla Osteotomy at an age of 8-12 year in the WCH UMC Utrecht for BCLP is reviewed. Long-term results and complications are described retrospectively. The timing protocol using root formation of the upper canine is analysed.

Chapter four: Maxillofacial growth of the BCLP Patients is compared with other studies on the growth of BCLP patients. The BAURU Yardstick in combination with cephalometrics is used to predict growth of the maxilla and to investigate the cause of growth disturbances of BCLP patients. A search for predictive factors that explain growth disturbance is part of chapter four.

Chapter five: The results of the Secondary Alveolar Bone Grafting and Premaxilla Osteotomy procedure on the level of the dentition are described. A new Dento-Maxillary Scoring System is used.

Chapter six: Finally, in this chapter the future of bone grafting is described. Until now autologous bone grafts from various donor sites are used. In the near future, it may be possible to use laboratory-created bone constructs.

REFERENCES

- [1] Schönbeck Y, Hindori-Mohangoo AD, Masurel N, et al. Aangeboren afwijkingen in Nederland 2001-2013: Gebaseerd op de landelijke perinatale registraties. 2015; 72.
- [2] Luijsterburg AJM, Trenning AH, Ongkosuwito EM, et al. NVSCA-REGISTRATIE SCHISIS JAARVERSLAG 2014 Nederlandse teams Nederlandse Vereniging voor Schisis en Craniofaciale Afwijkingen. 2014; 1-21.
- [3] Luijsterburg AJM, Trenning AH, Ongkosuwito EM, et al. NVSCA-REGISTRATIE SCHISIS JAARVERSLAG 2015 Nederlandse teams Nederlandse Vereniging voor Schisis en Craniofaciale Afwijkingen. 2015; 1-21.
- [4] Luijsterburg AJM, Trenning AH, Ongkosuwito EM, et al. NVSCA-REGISTRATIE SCHISIS JAARVERSLAG 2016 Nederlandse teams Nederlandse Vereniging voor Schisis en Craniofaciale Afwijkingen. 2016; 1-21.
- [5] Kouwenberg M, Draaisma JMT, Kuijpers-Jagtman AM, et al. Additional congenital abnormalities with a complete bilateral cleft lip and palate. *Tijdschr Kindergeneeskd* 2010; 78: 15-20.
- [6] Adrichem LNA. Lip-kaak- en gehemelte spleten in Nederland. *Ned Tijdschr voor Plast Chir* 2013; 1: 11-18.
- [7] Mink Van Der Molen AB, Maarse W, Pistorius L, et al. Prenatal screening for orofacial clefts in the Netherlands: A preliminary report on the impact of a national screening system. *Cleft Palate-Craniofacial J* 2011; 48: 183-189.
- [8] Maarse W, Boonacker CWB, Lapid O, et al. Professional opinion on oral cleft during pregnancy: A comparison between Israel and the Netherlands. *Prenat Diagn* 2015; 35: 544-548.
- [9] Mink Van Der Molen AB, Maarse W, Pistorius L, et al. Prenatal screening for orofacial clefts in the Netherlands: A preliminary report on the impact of a national screening system. *Cleft Palate-Craniofacial J* 2011; 48: 183-189.
- [10] Gomes KU, Rapoport A, Carlini JL, et al. Social integration and inclusion after pre-maxilla surgical repositioning in patients with bilateral cleft palate and lip. *Braz J Otorhinolaryngol* 2009; 75: 537-543.
- [11] Kappen IFPM, Bittermann GKP, Bitterman D, et al. Long-term follow-up study of patients with a unilateral complete cleft of lip, alveolus, and palate following the Utrecht treatment protocol: Dental arch relationships. *J Cranio-Maxillofacial Surg* 2017; 45: 649-654.
- [12] Brouns J, Egyedi P. Osteotomy of the premaxilla. *J Maxillofac Surg* 1980; 8: 182-186.
- [13] Cosman B. Premaxillary excision: reasons and effects. *Plast Reconstr Surg* 1984; 73: 195-206.
- [14] Bishara SE, Olin WH. Surgical repositioning of the premaxilla in complete bilateral cleft lip and palate. *Angle Orthod* 1972; 42: 139-147.
- [15] Innis CO. Repositioning of the premaxilla and simultaneous closure of bilateral cleft lips. *Br J Plast Surg* 1961; 14: 153-156.
- [16] Zajdela Z. Celesnik procedure in the surgical treatment of bilateral complete clefts. *J Maxillofac Surg* 1973; 1: 137-42.
- [17] Veau V. *Veau, V. Bec-de lievre: formes cliniques-chirurgie (avec la collaboration de J. Recamier)*. Masson et Cie, 1938.
- [18] Ralph Millard D. Complete unilateral clefts of the lip. *Plast Reconstr Surg* 1960; 25: 595-605.
- [19] MILLARD DR. Columella lengthening by a forked flap. *Plast Reconstr Surg Transplant Bull* 1958; 22: 454-7.
- [20] Heycock MH. A field guide to cleft-lip repair. *Br J Surg* 1971; 58: 567-70.

- [21] Furlow LT. Cleft palate repair by double opposing Z-plasty. *Plast Reconstr Surg* 1986; 78: 724–38.
- [22] Sommerlad BC. A technique for cleft palate repair. *Plast Reconstr Surg* 2003; 112: 1542–1548.
- [23] LANGENBECK &NA; Operation Der Angeborenen Totalen Spaltung Des Harten Gaumens Nach Einer Neuen Methode. *Plast Reconstr Surg* 1972; 49: 323–324.
- [24] Mink van der Molen AB, Janssen K, Specken TFJMC, et al. The modified Honig velopharyngoplasty - a new technique to treat hypernasality by palatal lengthening. *J Plast Reconstr Aesthetic Surg* 2009; 62: 646–649.
- [25] Scott R, Scott J, Stagnell S, et al. Outcomes of 44 consecutive complete bilateral cleft lip and palate patients treated with secondary alveolar bone grafting and premaxillary osteotomy. *Cleft Palate-Craniofacial J* 2017; 54: 249–255.
- [26] Scott JK, Webb RM, Flood TR. Premaxillary osteotomy and guided tissue regeneration in secondary bone grafting in children with bilateral cleft lip and palate. *Cleft Palate-Craniofacial J* 2007; 44: 469–475.
- [27] Spicer PP, Kretlow JD, Young S, et al. Evaluation of bone regeneration using the rat critical size calvarial defect. *Nat Protoc* 2012; 7: 1918–1929.
- [28] De Ruiter AP, Dik E, Van Es R, et al. Micro-structured calcium phosphate ceramic for donor site repair after harvesting chin bone for grafting alveolar clefts in children. *J Cranio-Maxillofacial Surg* 2014; 42: 460–468.
- [29] Dik EA, De Ruiter AP, Van Der Bilt A, et al. Effect on the contour of bone and soft tissue one year after harvesting chin bone for alveolar cleft repair. *Int J Oral Maxillofac Surg* 2010; 39: 962–967.
- [30] Geraedts CTM, Borstlap WA, Groenewoud JMM, et al. Long-term evaluation of bilateral cleft lip and palate patients after early secondary closure and premaxilla repositioning. *Int J Oral Maxillofac Surg* 2007; 36: 788–796.
- [31] Bathla S. Alveolar Bone. *Periodontics Revisit* 2011; 16: 27–27.
- [32] Padwa BL, Sonis A, Bagheri S, et al. Children with repaired bilateral cleft lip/palate: Effect of age at premaxillary osteotomy on facial growth. *Plast Reconstr Surg* 1999; 104: 1261–1269.
- [33] Freihofer HPM, van Damme PA, Kuijpers-Jagtman AM. Early secondary osteotomy-stabilization of the premaxilla in bilateral clefts. *J Cranio-Maxillofacial Surg* 1991; 19: 2–6.
- [34] Koole R. Ectomesenchymal mandibular symphysis bone graft: An improvement in alveolar cleft grafting? *Cleft Palate-Craniofacial J* 1994; 31: 217–223.
- [35] De Ruiter AP, Van Der Bilt A, Meijer G, et al. Orthodontic treatment results following grafting autologous mandibular bone to the alveolar cleft in patients with a complete unilateral cleft. *Cleft Palate-Craniofacial J* 2010; 47: 35–42.



CHAPTER 2

Management of the premaxilla in the treatment of bilateral cleft of lip and palate: what can literature tell us?

Published in Clinical oral investigations 2015
DOI: 10.1007/s00784-015-1589-y

Gerhard KP Bittermann, Adrianus P de Ruiter, Nard G Janssen, Arnold JN Bittermann, Aebele B Mink van der Molen, Robert JJ van Es, Ron Koole, Antoine JWP Rosenberg

INTRODUCTION

Patients with bilateral cleft of lip and palate (BCLP) require much attention. Between the prenatal diagnosis at 20 weeks of pregnancy and the birth of a child with a cleft, it cannot be taken for granted that the parents will accept the child [1]. Up to the age of 18, children and young people with BCLP require intensive treatment in the fields of diet, growth, psychosocial development, hearing and cosmetics [2]. An important aspect of the BCLP patient is a mobile premaxilla from birth, because of the alveolar clefts and therefore the premaxilla is fixed only to the vomer bone. There is often protrusion of the premaxilla because of a lack of sphincterfunction from the orbicularis oris muscle. This can cause even extreme abnormalities in the position of the premaxilla; sometimes the whole segment can be rotated resulting in functional and cosmetic disorders. Over time there have been many forms of treatment aiming at changing the position of the premaxilla. In the past, the premaxilla was sometimes resected [3]. Later, early osteotomy of the premaxilla was carried out (setback osteotomy) during or even before lip closure. This had a disastrous effect on the growth of the maxilla [4, 5]. Vargervik et al. analyzed the treatment result of BCLP patients and highlighted the severe growth disturbances in 12 early surgically treated patients [6]. Since then, the prevailing opinion is that carrying out osteotomy of the premaxilla before the age of 6 years should be avoided [7].

In patients with BCLP, closure of the alveolar clefts is usually carried out at a later stage - between the ages of 9-12 years - and involves a bone graft and a corrective osteotomy of the maxilla. [8, 9, 10, 11] .

The aims of this literature review were to collect data on the position of the premaxilla and the correction of the malposition concerning a) timing and technique, b) stability of the position achieved and remaining alveolar bone volume, c) the effects of surgery on maxillary growth, d) complications mentioned in the literature.

MATERIALS AND METHODS

Search protocol and selection of articles

Search and selection

A systematic search in PubMed, Embase and the Cochrane Library was conducted from 1960 up to January 2015. The search terms 'bilateral cleft lip and palate', premaxilla osteotomy', 'surgery', 'orthodontics', orthopedics, 'secondary alveolar bone grafting', 'bilateral alveolar cleft' with all relevant synonyms were used (table 1) [12]. Only articles written in English and German were collected for this literature search. Using predefined inclusion and exclusion criteria, one author (GB) screened all retrieved articles on title and abstract and excluded duplicate titles to select potentially eligible articles. Inclusion criteria were, availability of full text, case studies with groups of four patients or more and with follow-up to osteotomy of the premaxilla and addressing the success and complications of the

premaxillary osteotomy. Subsequently, the full text of relevant articles was screened for further selection. Finally, review articles on this topic and the references of selected articles were manually screened for titles not identified during the initial search (Figure 1). Excluded were all articles describing naso-alveolar moulding (NAM) as this is an early technique before lip closure.

Table 1 Key words used for the search of the three databases

Database	Terms
Pubmed	<p>((((((((((("bilateral alveolar cleft"[Title/Abstract]) OR "bilateral alveolar clefts"[Title/Abstract]) OR "secondary alveolar bone grafting"[Title/Abstract]) OR "blcp"[Title/Abstract]) OR "alveolar cleft"[Title/Abstract]) OR "alveolar clefts"[Title/Abstract]) OR "premaxilla"[Title/Abstract]) OR "premaxillary"[Title/Abstract]) OR "bilateral cleft"[Title/Abstract]) OR "bilateral cleft alveolus"[Title/Abstract]) OR "bilateral cleft lip/cleft palate"[Title/Abstract]) OR "intermaxillare"[Title/Abstract]) OR ("Cleft Palate/surgery"[Mesh] OR "Cleft Palate/therapy"[Mesh])))</p> <p>AND</p> <p>((((((((((((surgery[Title/Abstract]) OR "surgical"[Title/Abstract]) OR "surgeries"[Title/Abstract]) OR "operation"[Title/Abstract]) OR "operated"[Title/Abstract]) OR "operate"[Title/Abstract]) OR "reposition"[Title/Abstract]) OR "repositioning"[Title/Abstract]) OR "repositioned"[Title/Abstract]) OR "graft"[Title/Abstract]) OR "grafted") OR "grafting"[Title/Abstract]) OR "surgically"[Title/Abstract]) OR "orthodontic"[Title/Abstract]) OR "orthodontically"[Title/Abstract]) OR "orthodontics"[Title/Abstract]) OR "orthopedics"[Title/Abstract]) OR "orthopedic"[Title/Abstract])</p>
EMBASE	<p>('bilateral alveolar cleft':ab,ti OR 'bilateral alveolar clefts':ab,ti OR 'secondary alveolar bone grafting':ab,ti OR 'blcp':ab,ti OR 'alveolar cleft':ab,ti OR 'alveolar clefts':ab,ti OR 'premaxilla':ab,ti OR 'premaxillary':ab,ti OR 'bilateral cleft':ab,ti OR 'bilateral cleft alveolus':ab,ti OR 'bilateral lip cleft palate':ab,ti OR 'intermaxillare':ab,ti OR 'cleft palate'/exp)</p> <p>AND</p> <p>(surgery:ab,ti OR surgical:ab,ti OR surgeries:ab,ti OR operation:ab,ti OR operated:ab,ti OR operate:ab,ti OR reposition:ab,ti OR repositioning:ab,ti OR repositioned:ab,ti OR graft:ab,ti OR grafted:ab,ti OR grafting:ab,ti OR surgically:ab,ti OR surgically:ab,ti OR orthodontic:ab,ti OR orthodontically:ab,ti OR orthodontics:ab,ti OR orthopedics:ab,ti OR orthopedic:ab,ti) AND [embase]/lim NOT[medline]/lim</p>
Cochrane	Cleft palate mesh

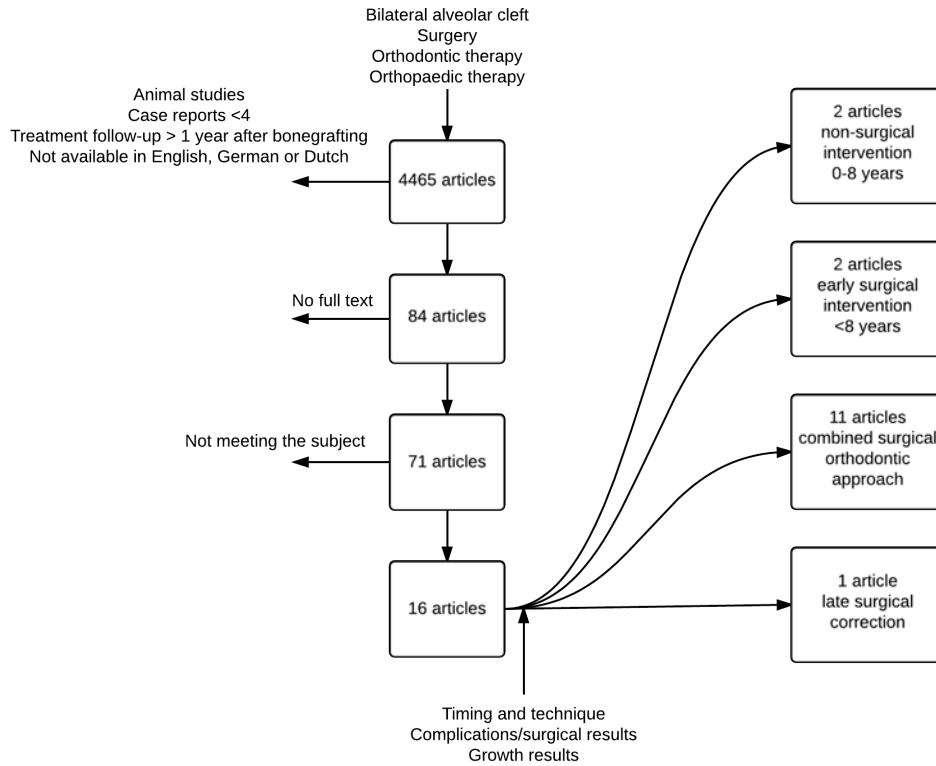


Figure 1. Schematic record of the search process: review articles and references from selected articles were manually screened for titles not identified during the initial search

RESULTS

The results of the literature search are summarised in Table 2 and Table 3. After screening the articles 16 of these were included in this analysis. 2 Articles concerning non-surgical interventions, 2 articles concerning early surgical interventions, 11 articles on combined orthodontic and surgical therapy and 1 concerning a late surgical intervention. Literature shows that there are three periods of time during which the position of the premaxilla can be corrected.

1. Early primary correction
 - 1.1. Early non-surgical correction during the first year of life and < 8 years.
 - 1.2. Early surgical correction <8 years
2. Early and late secondary combined treatment (between 8 and 12 years)
3. Late surgical correction (>12 years tertiary)

In these treatment periods we focussed on analysing:

- A. The position and stability of the premaxilla and the results of bone grafting the clefts.
- B. The effects of this treatment on the growth of the maxilla.
- C. Complications mentioned in the selected literature

1.1 Early non-surgical correction during the first year of life and < 8 years

During the first year of life, the position of the premaxilla can be guided by nasoalveolar moulding (NAM) or presurgical orthodontic treatment (PSOT) [13]. The application of NAM or PSOT prior to surgery is to enable easier primary lip closure between the age of 0 and 12 months. However, the long term results of these techniques on the position of the premaxilla are not shown in literature [14]. As this is an early therapy used before closure of the lip and the long term results on the position of the premaxilla are not clear, NAM and PSOT were excluded in this review [15].

After closure of the lip and reconstruction of the *orbicularis oris* muscle, a short-term growth effect is seen on the maxilla [16].

Dentofacial orthopaedic and orthodontic procedures are also carried out. Of the articles that were finally selected, two described the use of dentofacial orthopaedic and orthodontic procedures. [17, 18].

Grabowski et al, describe the long-term follow-up (17.3 years) of 18 patients who underwent orthopaedic and orthodontic interventions, without osteotomy [17]. In BCLP patients with permanent dentition, they used the Pont's Index to measure the width of the dental arch [19]. A lateral cephalogram was used to determine the overjet. In 4 of the 18 patients, high anterior compression of the upper jaw developed following the treatment. Two patients developed a cross-bite and an Angle Class III intermaxillary relationship was found in 3 patients. At the age of 17 years, 2 patients had a sagittal overbite and a vertical overbite of 0 mm. 9 Patients had a sagittal overbite of more than 2 and 3 mm, and seven had a vertical overbite of more than 2 mm and 3 mm. It was not necessary to widen the upper jaw or carry out orthognathic surgery in any of these patients. Guiding the growth of the bone during the first year of life results in more space in the upper jaw and fewer extractions later in life. Before 1990 the cleft was not closed, after 1990 an osteoplasty was carried out.

Liou et al describe 8 patients between the ages of 8 and 11 during the mixed dentition period with caudally prominent premaxilla, in whom the average overbite was 8.4 mm and the average vertical overbite was 3.7 mm [18]. These patients were treated with a dentally fixed distractor on the premaxilla and affixed to the upper molars which moved the intruding premaxilla cranially. In the whole group intrusion was completed within 4 weeks. The overbite was significantly reduced to 0.7 mm. After the intrusion, the occlusion surface and the gingival margins of the premaxilla and the lateral segments were level.

Table 2. Summary of the articles included in this literature analysis

Author (reference)	No of patients cases and study type	Intervention	Follow-up
Scott (<i>Scott, Webb, and Flood 2007</i>)	15 Retrospective follow-up	Secondary alveolar bone grafting + osteotomy	3 Years
Geraedts (<i>Geraedts et al. 2007</i>)	40 Retrospective follow-up	Early secondary alveolar bone grafting + osteotomy	8 Years
Brouns (<i>Brouns and Egyedi 1980</i>)	31 Retrospective follow-up	Osteotomy + bone graft, sometimes second operation	1 Year
Carlini (<i>Carlini et al. 2009</i>)	50 Retrospective follow-up	Secondary alveolar bone grafting + osteotomy	1 Year
Freihofer (<i>Freihofer, van Damme, and Kuijpers-Jagtman 1991</i>)	13 Retrospective follow-up	Secondary alveolar bone grafting + osteotomy	15 months
Heidbuchel (<i>Freihofer et al. 1993</i>)	22 Retrospective follow-up	Secondary alveolar bone grafting + osteotomy	7 Years
Grabowski (<i>Grabowski et al. 2006</i>)	18 Follow-Up	Orthopedics and orthodontics (osteoplasty)	17.3 Years
Cronin (<i>CRONIN 1957</i>)	5 Case study	Osteotomy and kirshner wire fixation	-
Liou (<i>Liou et al. 2004</i>)	8 Prospective follow up	Tooth-borne distraction device	1 Year
Padwa (<i>Padwa et al. 1999</i>)	24 Non-randomized controlled trial	Early vs. Late vs. no osteotomy of the os intermaxillare	2,8-5,7 Years
Akita (<i>Akita and Hirano 2006</i>)	17 Non-randomized controlled trial	Osteotomy of the premaxilla with secondary alveolar bone grafting vs. secondary alveolar bone grafting alone	0,5-3 years
Bishara (<i>Bishara and Olin 1972</i>)	20 Retrospective follow-up controlled study	Premaxilla osteotomy at time of lip closure vs. two-staged closure of the lip and no osteotomy	17 years
Koh (<i>Koh et al. 2013</i>)	8 Retrospective case study	Interdental distraction osteogenesis, alveolar bone grafting, premaxilla osteotomy	56 months
Aburezq (<i>Aburezq, Daskalogiannakis, and Forrest 2006</i>)	4 Retrospective follow up	Secondary alveolar bone grafting + osteotomy	10 months
Oyama (<i>Oyama et al. 2008</i>)	6 Case study	Secondary alveolar bone grafting + osteotomy	3 months
Narayanan (<i>Narayanan et al. 2006</i>)	14 Case study	Palatal repair and premaxilla setback	6 months

* SOB: Sagittal Overbite, VOB: Vertical Overbite

Premaxilla position	Other
-	93.96% of bone height is retained after 3 months
At age 17: 13 patients needed osteotomy	Cephalometric analysis Le fort needed in 9 patients
Angle class I/II group 17 patients good occlusion Angle class III group 13 patients good occlusion Angle class IV group 1 patient good occlusion	Bigger position corrections result in bigger chance of complications
-	-
-	Residual bone height in 15 patients more than 50%
SNA average increase 2.02 degrees 3.34 degree reduction of angle between spinal plane and SN plane	18 patients more than 50% maxilla height. Cephalometric analysis
9 patients SOB >2mm VOB > 2mm 7 patients SOB >3mm VOB >3mm*	Cephalometric results Criteria: Time of treatment, type of orthodontic treatment, method of closing the incisor gap in the left area, special methods.
-	-
Before treatment SOB average 8.4 mm VOB 3.7mm After treatment SOB 0.7mm	46% true orthopedic intrusion of the premaxilla, 54% dental intrusion of the premaxilla
-	Cephalometric results
-	0-25% bone resorption in the osteotomized group in 12/14 clefts. 0-25% bone resorption in the non osteotomized group in 10/20 clefts
-	Cephalometric analysis
-	Bone height 98% of patients between 50-100% left
-	2 patient → Grade 1 1 patient → Grade 2 1 patient → Grade 3
-	Bone height is good
10-15 mm setback. 5 had class III relationship. 2 had open bite	Good results

Table 3. An overview of the scored parameters collected from the selected literature

Article	Outcome parameter	Comment
Timing and technique of premaxillary correction		
Grabowski <i>et al.</i> , 2006	Orthopaedic and orthodontic treatment starting at an early age: N=18 Good results no osteotomy was needed. Two patients with crossbite Class III in three patients	
Liou <i>et al.</i> , 2004	Orthopaedic and orthodontic treatment between 8 and 11 years: N=8 correction of the premaxilla using a distractor Overbite reduction to 0.7mm	
Cronin <i>et al.</i> , 1957	Surgery during neonatal period	Bad outcome for maxillary growth
Bishara <i>et al.</i> , 1972	Osteotomy during neonatal period, compared to no osteotomy: SNA was significantly smaller in osteotomy group. SNB was negative Concave soft tissue profile	Early osteotomy has a bad outcome on maxillary growth
Heidbüchel <i>et al.</i> , 1993	Orthodontics and osteotomy: N=22 prior to surgery orthodontic intrusion of the premaxilla. After osteotomy SNA decreased by 2.02	After osteotomy better inclination of maxillary incisors
Scott <i>et al.</i> , 2007	Age between 8-12 years, good results surgical correction of the premaxilla.	Collagen membrane was used to close the nasal mucosal layer
Koh <i>et al.</i> , 2013	N=51, 36 patients treated with bone grafting only. N=7 wide cleft, good premaxillary position. Treated with a distractor N=8 surgical repositioning of premaxilla.	
Brouns <i>et al.</i> , 1980	N=31 surgical repositioning of premaxilla In the Angle Class I and II groups good occlusion In the Angle Class III group good occlusion In the class IV group good occlusion	
Akita <i>et al.</i> , 2006	N=17 divided into two groups N=10 no premaxilla osteotomy N=7 premaxillary osteotomy	
Aburezq <i>et al.</i> , 2006	N=4 Osteotomy combined with secondary alveolar bone grafting.	
Freihofer <i>et al.</i> , 1991	N=13 surgical repositioning of the premaxilla between 8 and 12 years N=8 preoperative orthodontics N=10 postoperative orthodontics	
Geraedts <i>et al.</i> , 2007	N=40 combination of pre-orthodontic treatment and repositioning of the premaxilla between 8 and 12 years	
Narayanan <i>et al.</i> , 2006	Tertiary osteotomy in children in developing countries.	Children were not operated on until the tertiary osteotomy

Table 3. Continued

Article	Outcome parameter	Comment
Stability of the position of the premaxilla and bone volume		
Scott <i>et al.</i> , 2007	N=15 iliac crest bone transplants, all successful 93.96% bone volume preserved after 3 months	
Koh <i>et al.</i> , 2013	In 96.1% of patients more than 50% transplant bone volume was preserved	
Brouns <i>et al.</i> (Brouns & Egyedi, 1980)	Of the Angle Class I and II patients N=17, N=11, consolidation no premaxillary instability Angle Class III group N=13, N=11 good consolidation N=2 remaining unstable premaxilla Class IV N=1 group stable premaxilla	
Carlini <i>et al.</i> , 2009	N=50, 45 patients no mobility of the premaxilla.	
Akita <i>et al.</i> , 2006	The amount of bone required to fill the cleft was significantly lower in the osteotomy group.	
Aburezq <i>et al.</i> , 2006	N=3 with good consolidation and more than 50% bone volume left. N=1 unstable premaxilla	After trauma
Freihofer <i>et al.</i> , 1991	N=9 rib bone N=3 mandibular bone N=1 local bone N=12 premaxilla stable and more than 50% of bone preserved	
Narayanan <i>et al.</i> , 2006	Uninhibited growth up to time of surgery on the premaxilla.	
Effects of surgery or orthodontic intervention on maxillary growth		
Cronin <i>et al.</i> , 1957	Surgery during neonatal period with disastrous effect on growth	
Bishara <i>et al.</i> , 1972	Surgery during neonatal period with bad effect on maxillary growth	
Geraedts <i>et al.</i> , 2007	N=27 acceptable profile at the end of follow-up N=13 hypoplastic midface for which a Le Fort I procedure was carried out No significant differences between osteotomy and non-osteotomy groups	
Padwa <i>et al.</i> , 1991	N=24 comparing three groups, for the effect of age on midfacial growth at time of surgery. Youngest group 6 years old. No delay in midfacial growth in any of the groups.	

Table 3. Continued

Article	Outcome parameter	Comment
Complications reported in the literature		
Heidbüchel <i>et al.</i> , 1993	Premaxillary necrosis in 1 patient (5%)	
Scott <i>et al.</i> , 2007	N=15, 3 patients with wound dehiscence	
Brouns <i>et al.</i> , 1980	In the class III group 11 patients with residual fistula, no necrosis of the premaxilla	
Carlini <i>et al.</i> , 2009	N=50 successful premaxilla repositioning and bone grafting in 48 patients. 2 patients with premaxillary necrosis.	
Aburezq <i>et al.</i> , 2006	No necrosis of the premaxilla. One patient with residual fistula	
Freihofer <i>et al.</i> , 1991	N=1 Necrosis of the bone transplants on both sides	
Geraedts <i>et al.</i> , 2007	N=1 recurrent oronasal fistula	

An overview of the scored parameters collected from the selected literature.

1.2 Early primary surgical correction <8 years

In the nineteen-fifties, surgical correction or resection of the premaxilla was carried out at an early stage. This took place during the closure of the lip or in the period thereafter. Two articles from the literature search report on the use of this technique [4, 20].

Cronin *et al.* described cases of a large protrusion where an osteotomy of the premaxilla was carried out during the neonatal period to improve lip closure. Pre-vomerine resection was carried out [20]. The premaxilla was moved dorsally and the vomer bone obtained in this way was grafted into the clefts. In the nineteen-seventies a comparable study was produced by Bishara *et al.* [4]. They looked at the cephalometric differences between patients in whom an osteotomy of the premaxilla had been carried out at the time of lip closure, and at patients in whom the premaxilla had not been manipulated. In the osteotomy group the age at which this had been carried out was 2.5 months; in the non-osteotomy group the lip had been closed in two stages. The first operation was at the age of 2.5 months and the second between 2.5 and 6 months. The average age at evaluation was 18.6 years in the osteotomy group and 17.2 years in the non-osteotomy group. At this age, midfacial growth is complete. In the osteotomy group the SNA (Sella-Nasion-A point) angle was found to be significantly smaller. This shows an unfavourable effect on the ventral growth of the maxilla. Unlike the non-osteotomy group, the ANB (A point-Nasion-B point) angle was negative which led to the conclusion that there was an unfavourable effect on growth. The soft tissue profile of the osteotomy group was concave in shape, whereas the non-osteotomy group profile was convex in shape. Measuring the position of the mandible, there proved to be no significant differences between the groups.

2. Early and late secondary combined treatment (between 8 and 12 years)

Combined treatment involves optimising the position of the premaxilla by means of orthodontic treatment followed by osteotomy of the premaxilla and bone grafting. Eleven articles from the literature search describe this method [2, 7, 9, 21, 22, 23, 24, 25, 26, 27, 28, 29].

The article of Heidbüchel et al. describes the combination of orthodontic and surgical treatment of BCLP patients with a follow-up of 7 years [29]. There were 22 patients included in the study. Prior to surgery the premaxilla was positioned cranially to the occlusion surface in 5 patients and at the same level or below the occlusal surface in 17 patients. In two cases, the premaxilla was already in Class III relationship. Preoperatively the upper jaw was widened in 12 patients, and the upper incisors had to be aligned in 5 patients. In 1 patient (5%), the premaxilla was lost after the osteotomy due to necrosis. On cephalometry the SNA angle was defined as a way of measuring the protrusion of the premaxilla. The SNA decreased by an average of 2.02 degrees following osteotomy and there was a reduction of 3.34 degrees in the angle between the spinal plane and the sella-nasion plane (SN). The angle between the upper incisors and the SN plane increased by 14.34 degrees, resulting in a more normal inclination of the maxillary incisors.

Scott et al. describe 15 patients with a follow-up of 3 years who underwent osteotomy of the premaxilla and a bone grafting from the iliac crest [28]. All the bone grafting procedures were successful and no necrosis of the premaxilla was observed. In 3 patients there was dehiscence of the wound which was treated conservatively. At three months, the average bone height was 93.96% and at three years 79% of the canines had erupted in the bone graft. Collagen membrane was used to close the nasal mucosal layer and in combination with an osteotomy of the premaxilla this ensured good closure nasally.

Koh et al. found the position of the premaxilla to be acceptable in 36 of 51 patients treated with an alveolar cleft closure by bone grafting from the iliac crest only [21]. In 7 patients who had a very wide cleft and in whom the premaxilla was well positioned, the two halves of the maxilla were drawn towards each other by means of a distractor to make the cleft smaller. (Erverdi et al., 2012). In the other 8 patients the position of the premaxilla was unfavourable and an osteotomy of the premaxilla was carried out. An alveolar bone graft was done in a separate procedure. The position of the premaxilla was regarded as unfavourable if the horizontal overbite (SOB) was more than 9 mm or less than - 3.5 mm. In 96.1% of the patients more than 50% of the bone graft was preserved (Abyholm Grade 1-2) [30].

Brouns et al. describe a corrective osteotomy in 31 BCLP patients [24]. They repositioned the premaxilla and in some cases, they also carried out an osteotomy of the lateral alveolar process. If there was adequate bone contact, no bone was grafted from the iliac crest. In

some cases this was done at a later time. The patients were divided into Class 1 to Class IV premaxilla-mandible relationship. Class IV is an Angle class III relationship with the premaxilla in a cranial position (front open bite). In the Angle Class I + II groups (N = 17) the premaxilla was well consolidated in 11 patients. In the other 6 patients there was persisting premaxillary instability. All 17 patients had good lateral occlusion. In the Angle Class III group (n = 13) consolidation achieved by a bone graft was good in 11 patients and in 13 patients occlusion was good. The remaining two patients had persistent instability of the premaxilla. In the class III group, 11 patients had a residual fistula. In the Class IV group (n = 1), consolidation and occlusion were both good. There was no necrosis of the premaxilla.

Carlini et al. describe 50 patients in whom a surgical repositioning of the premaxilla was carried out in combination with a bone graft [9]. In 24 patients bone from the mandibular symphysis was used for grafting and in 26 patients bone was harvested from the iliac crest. The operation was successful in 48 (96%) patients, but 2 patients developed necrosis of the premaxilla. In 45 of the 48 patients there was no mobility of the premaxilla postoperatively, therefore good consolidation had been achieved. There was some bone loss in three of the remaining patients (6%), but after a second operation treatment was successful. No difference was found between the bone from the mandibular symphysis and the bone from the iliac crest in the alveolar cleft closure procedure.

Akita et al. describe a comparison between two groups of patients [23]. The first group had a less pronounced abnormality of the premaxilla (n = 10) and no osteotomy of the premaxilla was carried out; in the second group that had a more pronounced abnormality (n = 7), this procedure was carried out. An osteotomy of the premaxilla was combined with a bone graft from the iliac crest. The amount of bone required to fill the cleft properly was significantly lower in the osteotomised group. There was also significantly less bone resorption in the osteotomy group.

In their article, Aburezq et al. describe 4 patients who were treated with an osteotomy of the premaxilla combined with secondary alveolar bone grafting [22]. There was no loss of the premaxilla and good consolidation was seen in 3 patients. In these patients there was less than 50% resorption of the grafted bone [30]. Following a trauma, postoperative instability of the premaxilla developed in one patient. This patient also developed a unilateral fistula and an infection. On the side of the fistula bone height was below 50% and on the contralateral side it was above 50%. All patients had a well-aligned dental arch.

Freihofer et al. describe 13 BCLP patients aged between 8 and 12 years who were treated with an osteotomy of the premaxilla [25]. Eight of these patients also underwent preoperative orthodontic treatment and 10 underwent postoperative orthodontic treatment. Rib bone was used in 9 patients and chin bone in 3 patients. In one case there was enough local bone to close the cleft. Of the 24 oronasal fistulas, 22 were closed and there were two recurrences

- both in the same patient. In 24 clefts a bone bridge developed, in one patient this remained absent bilaterally. In 12 patients the premaxilla remained stable. In 1 patient (8%), the bone grafts were resorbed bilaterally and the premaxilla became necrotic. In the other 12 patients grafted bone made up more than 50% of the height of the maxilla.

As it is possible to damage the growth centre when carrying out an osteotomy of the premaxilla, it is important to know what the long term results are and to pay special attention to growth. Geraedts et al. describe the long-term follow-up of early secondary closure in combination with an osteotomy of the premaxilla in 40 patients between 8 and 12 years old [26]. Rib bone was used in 11 patients and chin bone in 25 patients. In 4 patients only vomer bone was used. In 17 patients a pharyngoplasty was carried out at the age of 5-6 years, and in 4 patients a Le Fort I osteotomy was done at the age of 18 years. One patient developed a recurrent oronasal fistula. The facial profile was acceptable in 27 of the 40 patients and the sagittal and vertical dental relationships were essentially correct. Of these 40 patients, 13 had a hypoplastic midfacial deformity for which they underwent a Le Fort I osteotomy. Nine other patients were offered a Le Fort I osteotomy but they did not want to undergo further surgery. In the group with a non-acceptable profile, no further operations such as pharyngoplasty and secondary nose correction were carried out. This study used a control group of patients who did not undergo osteotomy of the premaxilla and there were no significant differences between the groups.

Padwa et al. did extensive research on midfacial growth following osteotomy of the premaxilla. This study compared 24 patients divided into three groups: 7 underwent osteotomy of the premaxilla before the age of 8 years (6.1 years), 10 were over the age 8 years (11.2 years), and 7 did not undergo osteotomy [7]. When the preoperatively measured SNA and SNB angles of each of the groups were compared it was shown that there was more anteposition and nasal rotation of the premaxilla in the early group. For this reason the movement of the premaxilla during the osteotomy was largest in this group. However, at the final postoperative check-up there were no significant differences in the position of the premaxilla between the groups, i.e. no delay of growth was measured in any of the age groups.

3. Late surgical correction (tertiary >12 years)

Late surgical correction is mainly carried out in developing countries where patients often only present with bilateral clefts at a later age. Uninhibited growth is possible until an older age. The literature search produced one article in which this is described [31].

Summarizing the results of the literature we focussed on the following items in the selected articles.

A. The position of the premaxilla and the results of bone grafting

The selected articles describe a total of 259 osteotomies of the premaxilla. The complications and results of 121 of these procedures are clearly described. In 100 patients the premaxilla was stable and in 121 patients more than 50% of the grafted bone was still present. Of this group of 259 patients, 81 patients underwent autologous bone grafting from the iliac crest, 38 from the mandibular symphysis, 20 from the ribs, and 3 from local bone. In the remainder the donor site is not reported. Total necrosis and loss of the premaxilla is described in four of these patients.

Some of the selected articles reported the results of premaxilla osteotomy and secondary alveolar bone grafting. Very few data are available on recurrent fistulas Table 4. The aim of carrying out an osteotomy of the premaxilla is to improve its position.

B. The effects of treatment on the growth of the maxilla

The selected articles [4, 20] describe the effect of early surgical intervention on growth of the premaxilla. It can be concluded from these articles that it is very disadvantageous for midfacial growth to undergo surgery to correct the position of the premaxilla before the age of 6 years. Selected articles describe the effects of an osteotomy of the premaxilla on midfacial growth at a later age. These articles report that there do not appear to be any significant differences in the results if an osteotomy is or is not carried out. [7, 26].

C. Complications summarized from literature

Of the 11 selected articles that describe surgical intervention to correct the position of the premaxilla, 7 report the occurrence of complications. These range from dehiscence of the wound, recurrent fistulas, loss of grafted bone due to resorption and instability of the premaxilla to complete necrosis and loss of the premaxilla. Table 4 summarizes the complications described in the selected articles.

DISCUSSION

In BCLP patients, the position of the premaxilla can be very abnormal [32]. This malposition could be a sagittal Angle class III intermaxillary relationship or a class I or II division cross-bite relationship, in both cases with a large variation in the vertical relationship with the mandibular frontal teeth. The premaxilla may also be in a torqued position. This wide variety in presentation occurs because the connection with the septo-premaxillary ligament is the factor that determines the direction of growth. The direction of growth is also determined by pressure from the tongue and lip [24, 33].

Table 4. Summary of complication rates collected from the articles selected for this review

Article	Number of patients	Complications described in article	Type bone graft (N)	Complication (N)	Patients with stable premaxilla	Less than 50% bone graft resorption
Scott <i>et al.</i> , 2007	15	15	Iliac crest (15)	Wounddehiscense (3)	12	15
Brouns <i>et al.</i> , 1980	31	31	Iliac crest (31)	No consolidation (9)	22	22
Carlini <i>et al.</i> , 2009	50	50	Iliac crest (26)/ Mandibular symphysis (24)	Bone loss (3)/ Premaxilla necrosis (2)	45	45
Freihofer <i>et al.</i> , 1991	13	13	Rib bone (9)/ Mandibular symphysis (3)/ Other (1)	Premaxilla necrosis (1)	12	12
Cronin <i>et al.</i> , 1957	40	-	-	-	-	-
Heidbuchel <i>et al.</i> , 1993	22	1	Rib (11)/ Iliac Crest (5)/ Mandibular symphysis (4)/ Maxillary (1)/ Bank Bone (1)	Premaxilla necrosis (1)	-	18
Padwa <i>et al.</i> , 1999	17	-	-	-	-	-
Akita <i>et al.</i> , 2006	7	7	Mandibular symphysis (7)	Bone loss (1)	6	6
Bishara <i>et al.</i> , 1972	20	-	-	-	-	-
Aburezq <i>et al.</i> , 2006	4	4	Iliac Crest(4)	Bone loss (1)	3	3
Geraeds <i>et al.</i> , 2007	40	-	-	-	-	-
Total	259	121	142	20	100	121

Summary of complication rates collected from the articles selected in this review N=number of patients.

Early primary correction before 8 years non-surgical

This type of correction using orthopaedic and orthodontic procedures achieves good results. Even earlier nasoalveolar moulding (NAM) instigated directly after birth makes primary lip closure between 0 and 12 months easier [15]. However, these results have also been questioned in literature [14, 34]. At a slightly older age, there are orthodontic procedures that influence the position of the premaxilla and the width of the upper jaw [35].

Orthopaedic interventions are used to guide the growth of the jaw from birth. A number of articles describe how to use growth to influence the position of the upper jaw and the premaxilla. This results in a great improvement in the position of the premaxilla; often osteotomy is no longer necessary. It is important to create good occlusion as soon as possible after the permanent dentition has erupted. While the patient still has deciduous teeth, orthodontics can be used to position the premaxilla. In this way, growth can be better guided [17]. The application of orthodontics at a young age requires an expert approach which focuses on oral hygiene and guidance [36].

Early surgical correction before 8 years and the effects of timing of surgery on growth

One of the areas from where the upper jaw grows is the premaxillary vomerine suture which is the site of osteotomy of the premaxilla [7, 26, 37]. This can potentially result in damage to this growth centre and retardation of growth at a later age. Growth from this centre is responsible for the forward and vertical growth of the entire midface [4, 16]. Literature shows that if an osteotomy of the premaxilla is carried out at a very early age (2.5 months at the same time as lip closure), retardation of midfacial growth can occur. It is recommended that this should be taken into account and an osteotomy of the premaxilla should be carried out after the age of 6 years when 90% of midfacial growth is complete [4, 7].

The long-term follow-up of patients treated by orthodontics or orthopaedics only shows that few growth problems are to be expected [7, 16, 38, 39].

Early and late secondary combined treatment (between 8 and 12 years)

By far the majority of articles describe combined treatment whereby the position of the premaxilla is corrected by orthodontic intervention before osteotomy of the premaxilla is carried out. As well as the premaxilla being in a good anatomical position, the continuity of the alveolar process is also relevant. Eleven of the selected articles describe this premise. However, the timing of the operation and the way in which it is carried out differs between studies. In order to achieve an uninterrupted dental arch, bone is grafted to both sides of the premaxilla. The canines or the lateral incisors will be able to erupt into the newly formed bone or can be moved therein by orthodontic treatment. The methods and timing of this vary. Current opinion is that early or late secondary alveolar bone grafting should be carried out between the ages of 9 and 11 years, prior to the eruption of the permanent upper canines and when the root has reached $\frac{1}{2}$ to $\frac{3}{4}$ of its final development. If the permanent lateral incisors are present at a younger age this should be carried out earlier of course: between the ages of 7 and 9 years [4, 26, 29, 37, 40, 41].

A bone graft can be carried out in combination with an osteotomy of the premaxilla, or in a separate session following the osteotomy. Without an osteotomy of the premaxilla the clefts can also be closed in one or two stages [21]. The underlying philosophy is that if large bilateral defects need to be filled, it is better to do so in two stages (Kamakura et al). However, this is rarely done because normally there is more than enough iliac bone to fill both sides of the defect. There are some clinical circumstances that force you to interrupt the surgery procedure, due to ischemia of the premaxilla, unreliable closure of the nasal and oral

mucosal layers. The common goal is to perform the osteotomy and bonegrafting in one procedure.

Complications and results of bone grafting

A complication mentioned in almost all the articles is the loss of grafted bone both unilaterally and bilaterally due to infection because of dehiscence of the wound (table 4). Recurrent instability of the premaxilla and recurrent oronasal fistulas are also mentioned. The most severe complication is necrosis and loss of the premaxilla due to compromised circulation in the buccal pedicle [9].

A long-term complication of osteotomy of the premaxilla can be that the growth of the upper jaw is retarded due to damage to the vomerine growth centre of the upper jaw.

CONCLUSION

With or without osteotomy of the premaxilla, with or without bone graft all the authors in this literature search have their own preferences and techniques for the treatment of BCLP patients. **There appears to be no common opinion.** The treatment of patients with a bilateral cleft differs internationally and between centres. Current treatment protocols are based on retrospective studies and expert opinion. The consensus of opinion is that alveolar bone grafting and osteotomy of the premaxilla should preferably be done at one session at around the age of 8 years or older. To the opinion of this review, carrying out an osteotomy of the premaxilla after the age of 8 years has more advantages. However, it is also our opinion that only after all orthodontic methods have been exhausted there should be an indication for carrying out osteotomy of the premaxilla. Bone grafting of the clefts is carried out at the same time as the osteotomy [25]. Surgical treatment in combination with secondary alveolar bone grafting has many advantages. The canines will erupt in the correct position ensuring that minimal prosthetic rehabilitation is required later on. Surgical correction in a vertical direction is found to be more difficult than in a posterior, anterior or transverse direction[7, 16].

If a vertical overbite of more than +4 mm, or a vertical open bite of more than -2 mm is measured, an osteotomy of the premaxilla is justified. This applies to every negative sagittal relationship of the premaxilla, to its reversed torqued position and if the premaxilla is rotated (axis 11 in relation to an SN of less than 100 degrees).

For the matter of A) premaxilla position and bone height, B) surgery timing and growth, and C) reported complications, from literature it appears that an osteotomy of the premaxilla should always be considered in combination with (and at the time of) early secondary alveolar bone grafting (8-12 years). This will give the best result in these three categories.


At the Wilhelmina Childrens Hospital Cleft Centre, Utrecht, the Netherlands carrying out an osteotomy and bone grafting the clefts in one procedure has generally been found to be technically difficult but good clinical results are achievable.

REFERENCES

- [1] Mink Van Der Molen AB, Maarse W, Pistorius L, et al. Prenatal screening for orofacial clefts in the Netherlands: A preliminary report on the impact of a national screening system. *Cleft Palate-Craniofacial Journal* 2011; 48: 183-189.
- [2] Gomes KU, Rapoport A, Carlini JL, et al. Social integration and inclusion after pre-maxilla surgical repositioning in patients with bilateral cleft palate and lip. *Brazilian Journal of Otorhinolaryngology* 2009; 75: 537-543.
- [3] Cosman B. Premaxillary excision: reasons and effects. *Plast Reconstr Surg* 1984; 73: 195-206.
- [4] Bishara SE, Olin WH. Surgical repositioning of the premaxilla in complete bilateral cleft lip and palate. *The Angle orthodontist* 1972; 42: 139-147.
- [5] Innis CO. Repositioning of the premaxilla and simultaneous closure of bilateral cleft lips. *British Journal of Plastic Surgery* 1961; 14: 153-156.
- [6] Vargervik K. Growth characteristics of the premaxilla and orthodontic treatment principles in bilateral cleft lip and palate. *Cleft Palate Journal* 1983; 20: 289-302.
- [7] Padwa BL, Sonis A, Bagheri S, et al. Children with repaired bilateral cleft lip/palate: Effect of age at premaxillary osteotomy on facial growth. *Plastic and Reconstructive Surgery* 1999; 104: 1261-1269.
- [8] Perko M. Gleichzeitige Osteotomie des Zwischenkiefers, Restspaltenverschluss und Zwischenkieferversteifung durch sekundäre Osteoplastik bei Spätfällen von beidseitigen Lippen-Kiefer-Gaumenspalten. *Deutsche Zahn-, Mund-, und Kieferheilkunde mit Zentralblatt für die gesamte Zahn-, Mund-, und Kieferheilkunde* 1966; 47: 1-5.
- [9] Carlini JL, Biron C, Gomes KU, et al. Surgical Repositioning of the Premaxilla With Bone Graft in 50 Bilateral Cleft Lip and Palate Patients. *Journal of Oral and Maxillofacial Surgery* 2009; 67: 760-766.
- [10] Jensen J, Kùseler A, Klit Pedersen T, et al. Premaxillary Osteotomy and Bone Grafting for Secondary BCLP Repair - Long-Term Evaluation of Growth. *Journal of Oral and Maxillofacial Surgery* 2011; 69: e16-e17.
- [11] Singh M, Flood T, Mahmood R, et al. Stabilisation of premaxillary segment in bilateral cleft palate during alveolar bone graft. *British Journal of Oral and Maxillofacial Surgery* 2012; 50: 678-679.
- [12] Janssen NG, Weijs WLJ, Koole R, et al. Tissue engineering strategies for alveolar cleft reconstruction: A systematic review of the literature. *Clinical Oral Investigations* 2014; 18: 219-226.
- [13] Grayson BH, Cutting CB. Presurgical nasoalveolar orthopedic molding in primary correction of the nose, lip, and alveolus of infants born with unilateral and bilateral clefts. *Cleft Palate-Craniofacial Journal* 2001; 38: 193-198.
- [14] Papadopoulos MA, Koumridou EN, Vakalis ML, et al. Effectiveness of pre-surgical infant orthopedic treatment for cleft lip and palate patients: A systematic review and meta-analysis. *Orthodontics and Craniofacial Research* 2012; 15: 207-236.
- [15] Shetty V, Vyas HJ, Sharma SM, et al. A comparison of results using nasoalveolar moulding in cleft infants treated within 1 month of life versus those treated after this period: Development of a new protocol. *International Journal of Oral and Maxillofacial Surgery* 2012; 41: 28-36.
- [16] Heidbuchel KLWM, Kuijpers-Jagtman AM, Van't Hof MA, et al. Effects of early treatment on maxillary arch development in BCLP. A study on dental casts between 0 and 4 years of age. *Journal of Cranio-Maxillo-Facial Surgery* 1998; 26: 140-147.

- [17] GRABOWSKI R, KOPP H, STAHL F, et al. Presurgical orthopaedic treatment of newborns with clefts - functional treatment with long-term effects. *Journal of Cranio-Maxillofacial Surgery* 2006; 34: 34-44.
- [18] Liou EJW, Chen PKT, Huang CS, et al. Orthopedic intrusion of premaxilla with distraction devices before alveolar bone grafting in patients with bilateral cleft lip and palate. *Plastic and Reconstructive Surgery* 2004; 113: 818-826.
- [19] Joondeph DR, Riedel RA, Moore AW. Pont's index: a clinical evaluation. *The Angle orthodontist* 1970; 40: 112-118.
- [20] CRONIN TD. Surgery of the double cleft lip and protruding premaxilla. *Plastic and reconstructive surgery (1946)* 1957; 19: 389-400.
- [21] Koh KS, Kim H, Oh TS, et al. Treatment algorithm for bilateral alveolar cleft based on the position of the premaxilla and the width of the alveolar gap. *Journal of Plastic, Reconstructive and Aesthetic Surgery* 2013; 66: 1212-1218.
- [22] Aburezq H, Daskalogiannakis J, Forrest C. Management of the prominent premaxilla in bilateral cleft lip and palate. *The Cleft palate-craniofacial journal : official publication of the American Cleft Palate-Craniofacial Association* 2006; 43: 92-95.
- [23] Akita S, Hirano A. Usefulness of simultaneous pre-maxillary osteotomy and bone grafting in the bilateral clefts. *Journal of Craniofacial Surgery* 2006; 17: 291-296.
- [24] Brouns J, Egyedi P. Osteotomy of the premaxilla. *Journal of maxillofacial surgery* 1980; 8: 182-186.
- [25] Freihofer HPM, van Damme PA, Kuijpers-Jagtman AM. Early secondary osteotomy-stabilization of the premaxilla in bilateral clefts. *Journal of Cranio-Maxillofacial Surgery* 1991; 19: 2-6.
- [26] Geraedts CTM, Borstlap WA, Groenewoud JMM, et al. Long-term evaluation of bilateral cleft lip and palate patients after early secondary closure and premaxilla repositioning. *International Journal of Oral and Maxillofacial Surgery* 2007; 36: 788-796.
- [27] Oyama T, Yoshimura Y, Onoda M, et al. Stabilization of a mobile premaxilla by cementing a bite splint with 1-stage bilateral alveolar bone grafting. *Journal of Craniofacial Surgery* 2008; 19: 1705-1707.
- [28] Scott JK, Webb RM, Flood TR. Premaxillary osteotomy and guided tissue regeneration in secondary bone grafting in children with bilateral cleft lip and palate. *Cleft Palate-Craniofacial Journal* 2007; 44: 469-475.
- [29] Heidbüchel KL, Kuijpers-Jagtman AM, Freihofer HP. An orthodontic and cephalometric study on the results of the combined surgical-orthodontic approach of the protruded premaxilla in bilateral clefts. *J Craniomaxillofac Surg* 1993; 21: 60-66.
- [30] Åbyholm FE, Bergland O, Semb G. Secondary bone grafting of alveolar clefts: A surgical/orthodontic treatment enabling a non-prosthetic rehabilitation in cleft lip and palate patients. *Scandinavian Journal of Plastic and Reconstructive Surgery and Hand Surgery* 1981; 15: 127-140.
- [31] Narayanan RK, Hussain SA, Murugesan S, et al. Synchronous palatal closure and premaxillary setback in older children with bilateral complete cleft of lip and palate. *Plastic and Reconstructive Surgery* 2006; 117: 527-531.
- [32] el Kassaby M, Abdelrahman N, Abbass I. Premaxillary characteristics in complete bilateral cleft lip and palate: A predictor for treatment outcome. *Annals of Maxillofacial Surgery* 2013; 3: 11.
- [33] Latham RA. Development and structure of the premaxillary deformity in bilateral cleft lip and palate. *British Journal of Plastic Surgery* 1973; 26: 1-11.
- [34] Prah C, Kuijpers-Jagtman AM, van 't Hof MA, et al. A randomized prospective clinical trial of the effect of infant orthopedics in unilateral cleft lip and palate: Prevention of collapse of the alveolar segments (Dutchcleft). *Cleft Palate-Craniofacial Journal* 2003; 40: 337-342.

- [35] Santiago PE, Schuster LA, Levy-Bercowski D. Management of the alveolar cleft. *Clinics in Plastic Surgery* 2014; 41: 219-232.
- [36] Badri P, Saltaji H, Flores-Mir C, et al. Factors affecting children's adherence to regular dental attendance: A systematic review. *Journal of the American Dental Association* 2014; 145: 817-828.
- [37] Heidbüchel KL, Kuijpers-Jagtman AM, Freihofer HP. Facial growth in patients with bilateral cleft lip and palate: a cephalometric study. *The Cleft palate-craniofacial journal : official publication of the American Cleft Palate-Craniofacial Association* 1994; 31: 210-216.
- [38] Bitter K. Repair of bilateral clefts of lip, alveolus and palate. Part 1: A refined method for the lip-adhesion in bilateral cleft lip and palate patients. *Journal of Cranio-Maxillofacial Surgery* 2001; 29: 39-43.
- [39] Lisson JA, Hanke I, Tränkmann J. Changes of vertical skeletal morphology in patients with complete unilateral and bilateral cleft lip and palate. *Cleft Palate-Craniofacial Journal* 2005; 42: 490-494.
- [40] Freihofer HPM, Borstlap WA, Kuijpers-Jagtman AM, et al. Timing and transplant materials for closure of alveolar clefts. A clinical comparison of 296 cases. *Journal of Cranio-Maxillofacial Surgery* 1993; 21: 143-148.
- [41] Bathla S. Alveolar Bone. *Periodontics Revisited* 2011; 16: 27-27.



CHAPTER 3

Incidence of complications in secondary alveolar bone grafting of bilateral clefts with premaxillary osteotomy: a retrospective cohort study

Published in Clinical Oral Investigations 2020

DOI: [10.1007/s00784-019-02977-y](https://doi.org/10.1007/s00784-019-02977-y)

Gerhard KP Bittermann, Robert JJ van Es, Adrianus P de Ruiter,
Michael H. Frank, Arnold JN Bittermann, Aebele B Mink van der Molen,
Ron Koole, Antoine JWP Rosenberg

INTRODUCTION

In cleft lip and palate patients, closure of the alveolar cleft involves an autologous bone graft. Secondary alveolar bone grafting (SABG) refers to closure of the alveolar cleft after palatal closing at an early age. However, there are differing opinions concerning the optimal timing and technique for closure of the alveolar cleft in complete bilateral cleft lip and palate (BCLP) patients [1]. In particular, handling of the position of the premaxilla in combination with SABG is technically difficult. Attention must be paid to the repositioning of the premaxilla, harvesting sufficient bone, and ensuring watertight closure of the gingiva [2, 3]. Perko and Freihofer et al. suggested a case grouping of SABG with respect to timing, which can be executed with or without a simultaneous premaxillary osteotomy (PO) [4, 5]. Early SABG takes place before the eruption of the canines, and late SABG is performed after eruption of the canines [6]. The term tertiary alveolar bone grafting is used in cases where SABG or osteotomy of the premaxilla has previously failed. PO is defined as an osteotomy of the premaxilla segment in combination with bone grafting and can be scheduled during early or late SABG [5, 7].

To define the success of SABG, several relevant parameters have been identified, including the presence of preoperative deciduous teeth around the cleft area, gingival health, a canine present in the cleft area, preoperative position of the premaxilla, preoperative bone quality around the cleft-related teeth, postoperative complications, and revision surgery [5, 8, 9, 10]. It is generally accepted that surgery should ideally be performed before eruption of the permanent canine [6] or before eruption of the lateral incisor, if present [8, 11].

Orthodontic pretreatment plays an important role in the surgical outcome of SABG + PO in BCLP patients [12]. Presurgically, the position of the premaxilla and the teeth it bears should be optimized by orthodontic alignment. After SABG + PO, orthodontic treatment aims to move the canine or lateral incisor into the grafted area [13, 14].

Several authors have assessed the clinical outcomes of SABG + PO using various endpoints (Table 1). Reported complication rates range from 10% to 46% [2, 5, 8, 9, 10, 14, 15, 16, 17, 18]. The only Cochrane review on this issue concluded that there was insufficient evidence for a definite conclusion on SABG because the groups in the articles reviewed were too small to draw any conclusions [18]. We conducted the present retrospective analysis of SABG + PO in BCLP patients to add data from the Department of Oral and Maxillofacial Surgery in the Wilhelmina Children's Hospital cleft team of the University of Utrecht, the Netherlands, to the current literature. This study aimed to evaluate our treatment protocols for 69 BCLP patients, with a focus on correlations between complications and each of several relevant parameters.

MATERIALS AND METHODS

This study was a nonrandomized, uncontrolled retrospective consecutive cohort study of all children with a complete BCLP who underwent SABG + PO at the Department of Oral

and Maxillofacial Surgery between 2004 and 2014. Patients from whom insufficient surgical data were available were excluded. Patients with some preoperative parameters missing (see below) were included in the analysis. In all, the records of 64 children were suitable for analysis. Follow-up time ranged from 3.1 to 13.4 years. Treatment consisted of SABG with a PO aimed at ages 8–12 years (range: 8–17 years, mean: 11.37 years, standard deviation: 1.77 years), ideally at a 67% (2/3) developmental stage of the root of the upper canine or of the lateral incisor, if present.

Table 1. Surgically related outcome measures and complication rates reported in studies on bilateral clefts treated with premaxillary osteotomy and bonegrafting

Author	Outcome measures	Incidence of complications (%)	Number of patients	Study design	Country of origin	Follow-up time
Present study	Complications: an adverse effect directly related to the surgical procedure	29,7	64	Retrospective cohort	Netherlands	3–13 years
Scott et al. 2017	Success of bonegraft, canine eruption, fistula, morbidity	27	44	Retrospective cohort	United Kingdom	1.4–14.6 years
Scott et al. 2007	Premaxilla mobility, wound dehiscence, recurrent oronasal fistulas	20	15	Retrospective cohort	United Kingdom	> 3 months
Freihofer et al. 1993	Failure: loss of 50% of bone graft, residual fistulas	15	22	Retrospective cohort	Netherlands	Mean: 21 months
Borba et al. 2014	Wound dehiscence, infection of the wound, resorption of the graft	36	71	Retrospective cohort	Brazil	≥ 1 year
Jia et al. 2006	Bergland criteria and eruption of the canine	46	28	Retrospective cohort	China	1–8 years
Shirani et al. 2012	Need for revision surgery because of insufficient bone height	44	44	Retrospective cohort	Iran	Mean: 33.35 months
Carlini et al. 2009	Integration of the bone graft, premaxilla mobility, residual fistulas	10	50	Prospective cohort	Brazil	1 year
Rawashdeh et al. 2006	Bergland criteria	20	15	Retrospective cohort	Jordan	6 months–5 years
Jia et al. 1998	Bergland criteria, wound dehiscence, infection	33	55	Retrospective cohort	United Kingdom	1–10 years

Surgical protocols

Primary closure

The surgical protocol involved closure of the lip at approximately 6 months according to a modified Millard or Tennison technique [19]. In the event of a wide cleft, lip adhesion was performed before closure of the lip. Closure of the soft palate was accomplished according to the procedure described by Sommerlad at 7–9 months [20]. Closure of the hard palate was performed as described by von Langenbeck at 3–6 years of age [21]. These procedures were performed by plastic surgeons from the cleft team and were not analyzed in this study.

PO and bone grafting

Preoperative orthodontic alignment of the alveolar process was conducted in most patients. Orthodontic repositioning of the premaxilla and its teeth was executed if possible. This was achieved using removable and/or fixed orthodontic appliances, thus creating a better preoperative frontal dental relationship. The aim of the orthodontic treatment was to align the maxillary segments by expansion of the lateral segments with removable appliances. Orthodontic treatment corrected crowding of the teeth and aligned the upper arch in three segments. The orthodontic treatment did not attempt to correct the vertical or horizontal malposition of the premaxilla.

The surgery was planned using a dental cast model on which a stainless steel splint was manufactured to stabilize the premaxilla during and after surgery. Surgery was carried out under general anesthesia by two experienced surgeons (RK and RvE), and patients were administered prophylactic intravenous clindamycin 13 mg/kg three times daily from the start of surgery and for 3 d postoperatively. The SABG + PO was performed to achieve a better view of and access to the nasal floor for a watertight closure of the nasal mucosal layer and to reposition the premaxilla. Using this technique, it was possible to place the premaxilla in a vertically and sagittally optimal position, preferably according to an Angle Class I frontal relationship. In all cases, the premaxilla was fixated apically to the vomerine bone with a 0.4-mm stainless steel wire. The alveolar cleft was grafted on both sides during the same surgical procedure. Preferably, a mandibular symphyseal bone graft was used for grafting [23, 24]. If an insufficient quantity of symphyseal bone was observed or if there was a risk of damaging the apical roots of the lower canines or incisors, iliac crest bone was harvested instead. The mucosal layers were closed with slowly resorbing Vicryl 4-0 sutures (Ethicon, Inc., Somerville, NJ, USA). The premaxilla was stabilized with the preoperatively manufactured splint. This splint was semi-rigidly fixated with stainless steel wires and acrylic resin for at least 6 weeks. During the first postoperative week, the wound was protected with an iodoform-petroleum jelly gauze covered with a zinc oxide-eugenol paste.

Preoperative parameters

Preoperative baseline data collected included: sex, race, and age at time of surgery. Preoperative parameters collected included: position of the premaxilla, preoperative bone quality around cleft-related teeth, gingival health, presence of a canine in the cleft, and

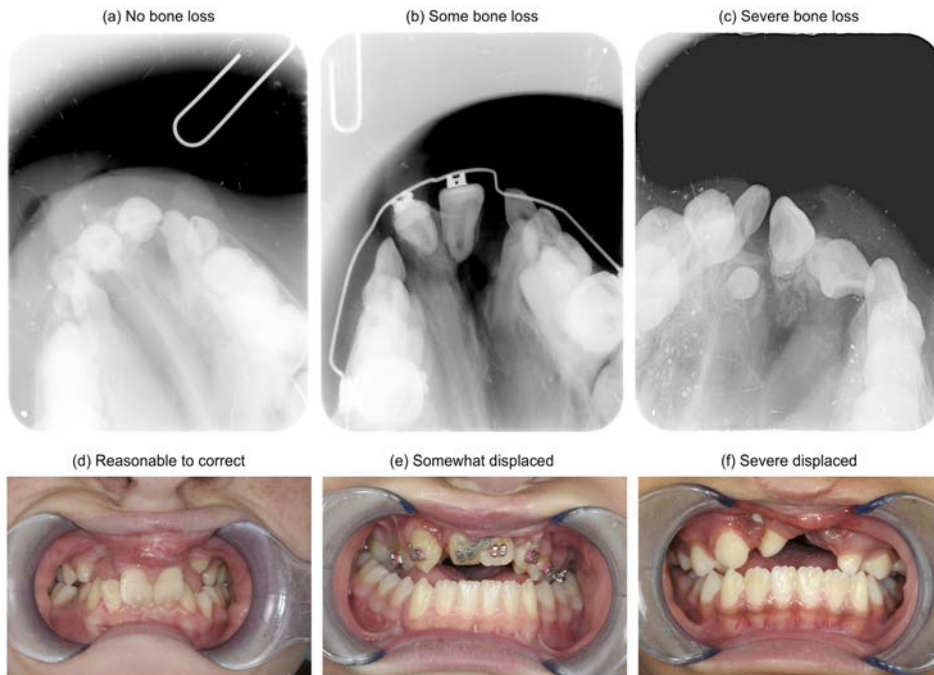


Figure 1. Preoperative bone quality around cleft-related teeth and preoperative position of the premaxilla

presence of deciduous teeth around the cleft area. Other data collected included: donor site of the graft (chin or iliac crest), timing of SABG (early or late), and follow-up period. All variables except race and the follow-up period were analyzed for correlation with complications. The cases with missing variables were excluded from the subgroup analysis. Four preoperative parameters—preoperative position of the maxilla, timing of the graft procedure, preoperative bone quality, and gingival health—were analyzed as follows:

- 1) Preoperative position of the premaxilla was evaluated using occlusal radiography and clinical photographs. X-ray scans and photographs were assessed initially by two authors (KB, RvE) until there was a consensus. The results were classified into three categories: reasonable to correct, somewhat displaced, and severely displaced. Anchor pictures were used to classify the premaxillary positions (Figure 1).
- 2) Timing of the grafting procedure was related to the age of the patient and determined using panoramic X-rays to evaluate the developmental stage of the root of the canine or of the lateral incisor, if present. If root formation of the canine or lateral incisor was developed 75%, and the position of the canine/lateral incisor was one crown length above the occlusal line, it was classified as an impacted canine/lateral incisor. If the canine/lateral incisor was in the line of occlusion and the root development was > 75%, it was classified as an erupted canine. Impacted canines were grouped as early SABG.

If the canine had erupted, it was grouped as late SABG. In the event the canine was missing, the lateral incisor was used. Anchor pictures were used as guidelines for classification (Figure 2).

- 3) Preoperative bone quality around the cleft-related teeth was estimated using occlusal X-ray scans. Alveolar bone height loss was classified as no bone loss, some bone loss, or severe bone loss. Anchor pictures were used for classification (Figure 1).
- 4) Gingival health and oral hygiene were judged using clinical photographs of the dentition. The gingiva was rated healthy, mildly inflamed, or clearly inflamed. Anchor pictures were used for classification (Figure 3).

The abovementioned parameters were analyzed twice by KB and RvE within a time span of one year to calculate an intraobserver correlation. A second observer (AR) also analyzed these parameters to calculate an interobserver correlation

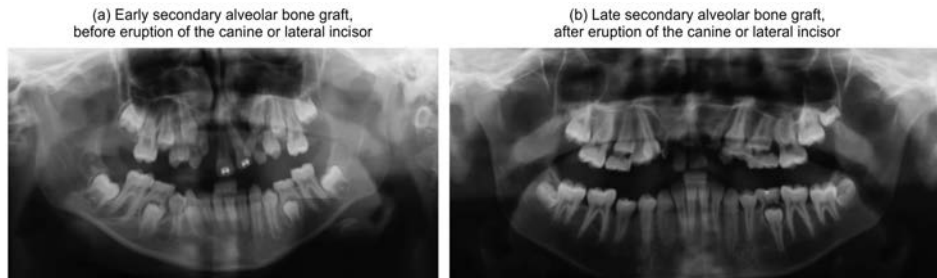


Figure 2. Time of grafting procedure (a) early secondary alveolar bone graft, before eruption of the canine or lateral incisor; (b) late secondary alveolar bone graft, after eruption of the canine or lateral incisor

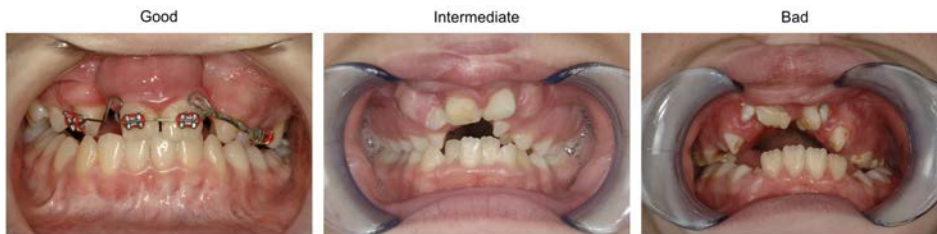

Figure 3. Gingival health and oral hygiene

Complications

A complication was defined as an adverse effect directly related to the surgical procedure. Revision surgery, or reoperation, was defined as surgery that had to be performed after the SABG and could be related to the SABG procedure.

Statistical analysis

The baseline characteristics of the 64 patients are reported as categorical variables. Univariate logistic regression was performed to assess the associations between these variables, with a chi-squared test if appropriate. If any trends were noted, receiver operating characteristic (ROC) curve analysis was used to determine the appropriate cut-off values for dividing patients into subgroups. Analysis of variance (ANOVA) was utilized to calculate the difference in average age between the early and late SABG + PO groups. Subgroup analysis was performed for preoperative parameters. SPSS for Mac (release 25.0.0.0, 2017, IBM Corp., Armonk, NY, USA) was used for all statistical analyses. All test statistics were two-tailed, and the significance level was set at $p < 0.05$. Inter- and intra-rater correlations were calculated using the Vassarstats online calculator (vassarstats.net, 2019) to calculate the Cohen's Weighted Kappa.

The strength of agreement was defined as poor agreement (Kappa < 0.20), fair (0.21–0.40), moderate (0.41–0.60), good (0.61–0.80), and excellent (0.81–100).

RESULTS

Baseline characteristics

Of 69 children with BCLP who had undergone SABG between 2004 and 2014, 65 had undergone SABG + PO. The surgical data of one patient were missing. Thus, 64 cases were suitable for analysis. The timing of SABG + PO ranged from 8 to 17 years (mean: 11.37 years, standard deviation: 1.77 years). Baseline characteristics of the 64 included patients are presented in Table 2. There were 26 girls and 38 boys, with a mean age at surgery of 11.37 years (range: 8–17 years); 49 patients were Caucasian and 15 were non-Caucasian. The mean follow-up time was 7.72 years (range: 3.1–13.4 years). The donor site was the iliac crest in 9 (14.1%) cases and the mandibular symphysis in 55 (85.9%) cases. Nineteen patients had complications that included wound dehiscence (three patients), oronasal fistulas (five), total alveolar bone graft loss (six), avascular necrosis of the premaxilla (two), and three other complications (Table 3). A detailed analysis of the relationship between preoperative parameters and complications is given below. Revision surgery was required for 18 patients. Four cases were syndrome-related: two cases had ectrodactyly–ectodermal dysplasia–cleft syndrome (OMIM: 129900), one had amniotic band syndrome (OMIM: 217100), and one case had oculo-genito laryngeal (Opitz) syndrome (OMIM: 300000) .

Regarding the preoperative parameters, photographs were incomplete for three patients; thus, gingival health could only be scored for 61 patients. Of these, 32 patients were classified in the category as having a healthy gingiva, 27 having a mildly inflamed gingiva, and two having clearly inflamed gingiva.

The preoperative position of the premaxilla was evaluated in all 64 patients. The premaxilla was found to be in a reasonable position in 33 patients, in an intermediate position in 27 patients, and in a severely displaced position in four patients.

Among the 63 radiographically evaluable patients, bone quality around the cleft-related teeth was good in 43 patients, fair in 18, and poor in two patients.

Table 4 shows the inter- and intra-rater correlations. The inter- and intra-rater correlations were as follows: preoperative position of the premaxilla (0.52, 0.67), timing of grafting (0.84, 0.78), preoperative bone quality around the cleft related teeth (0.27, 0.75), and gingival health (0.62, 0.62).

Table 2. Baseline characteristics

Variable	Number of patients (n = 64)	Percent of total	Years
Preoperative data			
Sex			
Male	38	59.4	
Female	26	40.6	
Patients with syndromes	4	6.25	
Race			
Caucasian	49	76.6	
Non-Caucasian	15	23.4	
Mean age at time of surgery			11.37 years
Follow-up period			3.1–13.4 years (mean: 7.72 years)

Table 3. Percentage of complications by type

	Complications (n)	Percent
Early major complications with revision surgery^a	18	28.1
Total graft loss	6	9.38
Bone resorption	1	1.56
Wound dehiscence	3	4.69
Bone sequestration	1	1.56
Necrosis of the premaxilla	2	3.13
Oronasal fistula	5	7.81
Late minor complications	1	1.56
Infra position of the premaxilla	1	1.56
Total Complications	19	29.7

^a Revision surgery; defined as surgery that had to be performed after the secondary alveolar bone grafting and could be related to this procedure. Except for the case of premaxillary necrosis, this consisted only of wound debridement. Each complication is counted as a separate patient.

Table 4. Correlations between inter-rater and-intra rater measurements

	Weighted Kappa	Standard error of kappa	95% CI
Intra-rater correlation			
Malposition of the premaxilla	0.52	0.09	0.35–0.69
Preoperative bone quality around cleft-related teeth	0.27	0.06	0.14–0.40
Gingival health	0.66	0.09	0.43–0.80
Time of grafting	0.84	0.07	0.70–0.97
Inter-rater correlation rater 1 vs. 2			
Malposition of the premaxilla	0.67	0.07	0.52–0.81
Preoperative bone quality around cleft-related teeth	0.75	0.07	0.61–0.88
Gingival health	0.62	0.09	0.45–0.79
Time of grafting	0.78	0.08	0.62–0.93

Analysis performed by rater 1 and 2 using the Vassarstats calculator

Analysis of postoperative complications

Table 5 shows the relationship of preoperative parameters to encountered complications. Because not all clinical information was retrievable, some parameters were not evaluable in all patients. Because of the small numbers of patients in some categories, some of the aforementioned categories were combined for the analysis. Specifically, 'poor' and 'fair' preoperative bone quality around cleft-related teeth were grouped together, as were 'intermediate' and 'severe' displacement of the premaxilla.

There were three parameters that showed a significant relationship with the rate of complications: preoperative bone quality around the cleft-related teeth ($p = 0.005$), preoperative position of the premaxilla ($p = 0.042$), and SABG + PO timing ($p = 0.041$). Logistic regression analysis revealed the respective odds ratios (ORs) and 95% confidence intervals (CIs) for these parameters (Table 6). The logistic regression also revealed a significant trend (OR: 1.4; 95% CI: 1.013–1.92; $p = 0.041$) towards more complications at older ages. As expected, the average age of the early SABG + PO group differed from that of the late SABG + PO group. Early SABG + PO was performed at a mean age of 10.81 ± 1.39 years ($n = 37$), and late SABG + PO was performed at 12.19 ± 2.00 years ($n = 26$) ($p = 0.002$; ANOVA) (Table 7). Therefore, we performed a ROC curve analysis, which revealed a cut-off age of 12 years. Subsequent logistic regression showed a significant increase in the rate of complications (OR: 5.9; 95% CI: 1.49–23.93; $p = 0.011$) among patients > 12 years of age. Similarly, revision surgery was more frequently necessary in such patients (OR: 6.68; 95% CI: 1.65–26.99; $p = 0.008$).

Gingival health appeared to be not related to the incidence of complications (chi-squared $p = 0.865$; OR: 1.1; 95% CI: 0.368–3.288; logistic regression $p = 0.865$).

Table 5. Assessment of preoperative parameters and their correlation with incidence of complications: univariate analysis (N=64)

Variable	Category	Number of patients (total for variable) ^a	Number (%) of patients with complications ^b	p-Value
Sex	Male	38 (64)	12 (31.58)	0.689
	Female	26 (64)	7 (26.92)	
Preoperative bone quality around cleft-related teeth	Good	43 (63)	8 (18.60)	0.003*
	Poor/fair	20 (63)	11 (55)	
Position of the premaxilla	Reasonable position	33 (64)	6 (18.18)	0.038*
	Displaced (intermediate/severe)	31 (64)	13 (41.94)	
Canine present in cleft	Yes	18 (64)	4 (22.22)	0.358
	No	44 (64)	15 (34.09)	
Gingival health	Good	32 (61)	10 (31.25)	0.617
	Average	27 (61)	9 (33.33)	
	Bad	2 (61)	0 (0)	
Deciduous teeth around cleft area	Yes	52 (62)	14 (26.92)	0.147
Time of grafting	Early secondary	37 (63)	7 (18.92)	0.020*
	Late secondary	26 (63)	12 (46.15)	
Graft type	Chin	55 (64)	16 (29.09)	0.796
	Iliac crest	9 (64)	3 (33.33)	

^a Because of incomplete clinical records, some parameters were not accessible for some patients. The total number of patients for each variable is indicated in parentheses following the number of patients.

^b Percentages were calculated using the number of patients in the corresponding subgroup

* Statistically significant based on the chi-squared test

DISCUSSION

The present study provides a retrospective analysis of cases of 64 children with BCLP who were treated in Wilhelmina Children's Hospital for closure of their alveolar clefts. This is one of the larger groups of BCLP patients with SABG + PO studied [1, 12]. Our patient group had an overall complication rate of 29%, which is similar to rates reported in previous studies. This study found a significant association between the incidence of complications and the age at surgery, preoperative bone quality around the cleft-related teeth, and preoperative malposition of the premaxilla. Previous reports used different definitions for reporting complications: insufficient bone height of the alveolar process only, or patients with residual fistulas [14, 22]. Complication rates after SABG + PO in BCLP patients are reported to vary

Table 6. Association between preoperative factors and the likelihood of developing complications: multivariate analysis

	Cases with complications	Cases without complications	OR	95% CI	p-Value
Age vs. complications	19	45	1.4	1.013–1.92	0.041*
Age > 12 years vs. complications ^a	11	53	5.9	1.49–23.93	0.011*
Preoperative bone quality around cleft-related teeth vs. complications	20	43	5.3	1.66–17.21	0.005*
Malposition of the premaxilla vs. complications	19	45	3.3	1.04–10.13	0.042*
Age vs. reoperation	18	46	1.4	1.02–1.97	0.034
Age > 12 years vs. reoperation ^a	18	46	6.68	1.65–26.99	0.008*
Gingival health vs. complications	19	42	1.1	0.368–3.288	0.865

CI: confidence interval; OR: odds ratio

^a Cut-off age of 12 years was determined by receiver operating characteristic curve analysis

* Statistically significant based on logistic regression analysis

Table 7. Time of grafting, by age and significant difference between groups

Time of grafting	Number of patients	Mean age (years)	Standard deviation (years)	p-Value
Early secondary	37	10.81	1.39	0.002*
Late secondary	26	12.19	2.00	
Missing	1	11.00	—	

* Statistically significant based on analysis of variance

from 10% to 46% and are generally higher in bilateral clefts than those observed in unilateral cleft lip and palate patients [8, 10, 23]. In the present study, we defined all variables resulting in an unsatisfactory outcome of alveolar bone graft surgery—i.e. requiring secondary surgery or conservative measures such as antibiotics—as complications.

Our analyses also revealed that the age at surgery had an influence on the complication rate. The subsequent ROC curve analysis revealed a cut-off point of 12 years, above which there was a significant increase in the rate of complications and the need for reoperation. This finding is also in concordance with those of previous studies [8, 22].

Malposition of the premaxilla

Appropriate orthodontic preparation is an important factor in successful SABG + PO [14]. In particular, widening the narrow alveolar cleft provides better surgical access and easier grafting of the cleft [24]. In the present study, 42% of patients with a displaced premaxilla required revision surgery, despite semirigid stabilization with a preoperatively manufactured splint. Other authors have also emphasized the substantial effects of preoperative malposition of the premaxilla on the development of complications [16, 25]. The preoperative position of the premaxilla is often displaced or twisted and requires orthodontical or surgical repositioning. After repositioning a severely displaced premaxilla, it can be difficult to find sufficient soft tissues to achieve watertight and tension-free closure of the grafted cleft. Watertight and tension-free wound closure decreases the risk of wound dehiscence and prevents perfusion failure of the gingival flaps [2]. Wound dehiscence will subsequently result in infection or loss of the grafted bone [26]. Sindet-Pedersen and Enemark reported that patients undergoing bilateral late SABG had the highest rate of complications (37.5%) among their study group [8]. They found that delayed bone healing is mostly related to infection in the grafted region. This is due to the fact that BCLP patients have relatively little mucosal tissue available to cover the grafted area

When SABG is combined with an osteotomy of the premaxilla, the nasal mucosa is more accessible, rendering an easier watertight closure [1, 8, 27, 28]. The osteotomy can be combined with application of a resorbable membrane such as a collagen membrane. This provides an adequate exposure of the nasal floor and an extra protective layer [2, 25]. Moreover, Shirani et al. described the need for revision surgery in 44% of their BCLP patients and stressed the importance of a semirigid fixation of the premaxilla after osteotomy and alveolar bone grafting [14]. We therefore believe that preoperative alignment of the malpositioned premaxilla before SABG + PO might reduce complication rates. Whether or not to strive for an optimal pre-operative orthodontical alignment of the premaxilla, will be the subject of further study.

Timing: early vs. late

The ages of 8–11 years are considered appropriate to carry out SABG + PO [29, 30]. It is possible to operate even earlier without influencing the growth of the maxilla [27, 31]. The present study demonstrates a significant relationship between late (> 12 years) SABG and the development of complications. Previous studies have found a significantly higher complication rate in older patients, especially in the late secondary and tertiary alveolar bone grafting groups [8, 32, 33]. Miller et al. demonstrated that the ideal time for SABG is before eruption of the canine or, if present, the permanent lateral incisor. If the lateral incisor or canine erupts into the grafted cleft, this also results in better residual bone volume after SABG [11]. Success rates as low as 39% for groups with the oldest patients and as high as 100% for groups with the youngest patients have been reported by others [7, 8, 11, 17].

Oral hygiene

Many BCLP patients appear to neglect their disorder and, consequently, have poor oral hygiene [34]. Moreover, if there is a malposition of the premaxilla and/or crowding of teeth, oral hygiene around the cleft-related teeth is technically difficult, also because of the lack of a vestibule in the premaxillary region [35]. Based on the images of gingival health, 35% of the patients in our population had insufficient oral hygiene. The condition of the gingiva and the graft-covering mucosa seem associated with the success rate of SABG + PO, poor oral health is reported to be a risk factor for infection of the bone graft [10]. In the present study, there was a trend towards an increased rate of complications with poor gingival health, but the relationship proved to be not significant.

Bone quality around the cleft

The present study found a significant relation between preoperative bone quality around the cleft-related teeth and the development of a postoperative complication. However, this has to be interpreted with great care, because the intra-rater correlation was 0.27, which is a poor correlation. One radiographic study found significant bone loss around teeth at the cleft site in cleft patients [34]. Quirynen et al. found differences between former clefts and adjacent teeth compared with the contralateral non-operated side. They stated that local factors may influence the condition of the periodontium and the development of gingival inflammation in cleft patients [36]. Although in unilateral clefts no long-term significant differences between the cleft side and the healthy side were found, there are significant short-term differences in probing depth around the cleft-related teeth and also in the amount of plaque compared to the no cleft side [37]. This is in accordance with our findings, and it is possible that those short-term factors influence the development of complications after SABG + PO.

Preoperative extractions

If supernumerary or deciduous teeth are present in the cleft area, some authors advise that these teeth be extracted at least 4–6 weeks before the SABG + PO procedure is done [11, 23]. This renders the flap designing for graft cover easier, with fewer perforations and less risk of wound dehiscence, resulting in fewer immediate postoperative complications [23]. In the present study population, special attention was paid to the preoperative extraction of deciduous teeth. Therefore, we were unable to analyze the influence of preoperative extractions, as all clefts were already cleared of deciduous teeth.

Limitations

Because of the retrospective design of this study, clinical data could not be retrieved in some cases and were noted as missing. This methodological flaw may have caused a selection bias in choosing early versus late alveolar bone grafting. The effect of this bias on the outcome remains unclear. The length of follow-up had a wide range of 3–13 years, which may include confounders. In addition, radiological examinations were carried out with two-

dimensional images, which renders analysis of the bone quality around the teeth difficult, resulting in a low correlation. The results of the bone quality should therefore be interpreted carefully.

It must be realized that this study included a heterogeneous group of patients with BCLP including Caucasians, non-Caucasians, and syndrome-related cases. Therefore, the results must be interpreted with caution. Unfortunately, patient-related outcomes were not available to correlate patient satisfaction with outcomes.

CONCLUSIONS

This study underlines timing of SABG + PO being essential. Early SABG + PO results in fewer complications than does late SABG + PO and should be preferred. Moreover, a severely displaced and cranially rotated premaxilla is a predictor of complications. Preoperative orthodontic repositioning of the severely displaced and cranially rotated premaxilla might be considered.

REFERENCES:

- [1] Bittermann GKP, de Ruiter AP, Janssen NG, et al. Management of the premaxilla in the treatment of bilateral cleft of lip and palate: what can the literature tell us? *Clinical Oral Investigations* 2016; 20: 207–217.
- [2] Scott JK, Webb RM, Flood TR. Premaxillary osteotomy and guided tissue regeneration in secondary bone grafting in children with bilateral cleft lip and palate. *Cleft Palate-Craniofacial Journal* 2007; 44: 469–475.
- [3] Scott R, Scott J, Stagnell S, et al. Outcomes of 44 consecutive complete bilateral cleft lip and palate patients treated with secondary alveolar bone grafting and premaxillary osteotomy. *Cleft Palate-Craniofacial Journal* 2017; 54: 249–255.
- [4] Perko M. Gleichzeitige Osteotomie des Zwischenkiefers, Restspaltenverschluss und Zwischenkieferversteifung durch sekundäre Osteoplastik bei Spätfällen von beidseitigen Lippen-Kiefer-Gaumenspalten. *Deutsche Zahn-, Mund-, und Kieferheilkunde mit Zentralblatt für die gesamte Zahn-, Mund-, und Kieferheilkunde* 1966; 47: 1–5.
- [5] Freihofer HPM, Borstlap WA, Kuijpers-Jagtman AM, et al. Timing and transplant materials for closure of alveolar clefts. A clinical comparison of 296 cases. *Journal of Cranio-Maxillofacial Surgery* 1993; 21: 143–148.
- [6] Freihofer HPM, van Damme PA, Kuijpers-Jagtman AM. Early secondary osteotomy-stabilization of the premaxilla in bilateral clefts. *Journal of Cranio-Maxillofacial Surgery* 1991; 19: 2–6.
- [7] Dempf R, Teltzrow T, Kramer FJ, et al. Alveolar bone grafting in patients with complete clefts: a comparative study between secondary and tertiary bone grafting. *Cleft Palate Craniofac J* 2002; 39: 18–25.
- [8] Sindet-Pedersen S, Enemark H. Comparative study of secondary and late secondary bone-grafting in patients with residual cleft defects. Short-term evaluation. *International Journal of Oral Surgery* 1985; 14: 389–398.
- [9] Borba AM, Borges AH, da Silva CSV, et al. Predictors of complication for alveolar cleft bone graft. *The British journal of oral & maxillofacial surgery* 2014; 52: 174–178.
- [10] Jia YL. Long-term outcome of secondary alveolar bone grafting in patients with various types of cleft. *The British journal of oral & maxillofacial surgery* 2006; 44: 308–312.
- [11] Miller LL, Kauffmann D, St John D, et al. Retrospective review of 99 patients with secondary alveolar cleft repair. *Journal of oral and maxillofacial surgery: official journal of the American Association of Oral and Maxillofacial Surgeons* 2010; 68: 1283–1289.
- [12] Geraedts CTM, Borstlap WA, Groenewoud JMM, et al. Long-term evaluation of bilateral cleft lip and palate patients after early secondary closure and premaxilla repositioning. *International Journal of Oral and Maxillofacial Surgery* 2007; 36: 788–796.
- [13] de Ruiter A, van der Bilt A, Meijer G, et al. Orthodontic Treatment Results Following Grafting Autologous Mandibular Bone to the Alveolar Cleft in Patients With a Complete Unilateral Cleft. *The Cleft Palate-Craniofacial Journal* 2010; 47: 35–42.
- [14] Shirani G, Abbasi AJ, Mohebbi SZ. Need for Revision Surgery After Alveolar Cleft Repair. *Journal of Craniofacial Surgery* 2012; 23: 378–381.
- [15] Carlini JL, Biron C, Gomes KU, et al. Surgical Repositioning of the Premaxilla With Bone Graft in 50 Bilateral Cleft Lip and Palate Patients. *Journal of Oral and Maxillofacial Surgery* 2009; 67: 760–766.
- [16] Rawashdeh MA, Telfah H. Secondary alveolar bone grafting: the dilemma of donor site selection and morbidity. *The British journal of oral & maxillofacial surgery* 2008; 46: 665–670.

- [17] Jia YL, James DR, Mars M. Bilateral alveolar bone grafting: A report of 55 consecutively-treated patients. *European Journal of Orthodontics* 1998; 20: 299–307.
- [18] Guo J, Li C, Zhang Q, et al. Secondary bone grafting for alveolar cleft in children with cleft lip or cleft lip and palate. *Cochrane Database of Systematic Reviews*. Epub ahead of print 2011. DOI: 10.1002/14651858.CD008050.pub2.www.cochranelibrary.com.
- [19] Millard D. Complete Unilateral Clefts of the Lip. *Plastic and reconstructive surgery* 1960; 25: 595–605.
- [20] Sommerlad BC. A technique for cleft palate repair. *Plastic and Reconstructive Surgery* 2003; 112: 1542–8.
- [21] von Langenbeck B. Operation der angeboren totalen Spaltung des harten Gaumens nach einer neuen Methode. *Drsch Klin* 1861; 8: 231.
- [22] Calvo AM, Trindade-Suedam IK, da Silva Filho OG, et al. Increase in Age Is Associated With Worse Outcomes in Alveolar Bone Grafting in Patients With Bilateral Complete Cleft Palate. *Journal of Craniofacial Surgery* 2014; 25: 380–382.
- [23] Almasri M. Reconstruction of the alveolar cleft: Effect of preoperative extraction of deciduous teeth at the sites of clefts on the incidence of postoperative complications. *British Journal of Oral and Maxillofacial Surgery* 2012; 50: 154–156.
- [24] Kindelan J, Roberts-Harry D. A 5-year post-operative review of secondary alveolar bone grafting in the Yorkshire region. *British journal of orthodontics* 1999; 26: 211–217.
- [25] Koh KS, Kim H, Oh TS, et al. Treatment algorithm for bilateral alveolar cleft based on the position of the premaxilla and the width of the alveolar gap. *Journal of Plastic, Reconstructive and Aesthetic Surgery* 2013; 66: 1212–1218.
- [26] van der Meij AJ, Baart JA, Prah-Andersen B, et al. Bone volume after secondary bone grafting in unilateral and bilateral clefts determined by computed tomography scans. *Oral surgery, oral medicine, oral pathology, oral radiology, and endodontics* 2001; 92: 136–141.
- [27] Bathla S. Alveolar Bone. *Periodontics Revisited* 2011; 16: 27–27.
- [28] Steinhauser EW. The modified “Wunderer” osteotomy for stabilization of the cleft-premaxilla - A new operative technique. *J Cranio-Maxillofac Surg*, <http://sfx.library.uu.nl/utrecht?sid=EMBASE&issn=10105182&id=doi:10.1016%2Fj.jcms.2014.02.002&atitle=The+modified+%22Wunderer%22+osteotomy+for+stabilization+of+the+cleft-premaxilla+-+A+new+operative+technique&stitle=J.+Cranio-Maxillofac.+Surg.&title=Journal+of+Cranio-Maxillofacial+Surgery&volume=&issue=&spage=&epage=&aulast=Steinh%C3%A4user&aufirst=Emil+W.&aunit=E.W.&aufull=Steinh%C3%A4user+E.W.&coden=JCMSE&isbn=&pages=-&date=2014&aunit1=E&aunitm=W.> (2014).
- [29] Borstlap WA, Heidbuchel KLWM, Freihofe PM, et al. Early Secondary Bone Grafting of Alveolar Cleft Defects A Comparison between Chin and Rib Grafts. 1990; 18: 201–205.
- [30] Bergland O, Semb G, Abyholm FE. Elimination of the residual alveolar cleft by secondary bone grafting and subsequent orthodontic treatment. *The Cleft palate journal* 1986; 23: 175–205.
- [31] Padwa BL, Sonis A, Bagheri S, et al. Children with repaired bilateral cleft lip/palate: Effect of age at premaxillary osteotomy on facial growth. *Plastic and Reconstructive Surgery* 1999; 104: 1261–1269.
- [32] Meyer S, Mølsted K. Long-term outcome of secondary alveolar bone grafting in cleft lip and palate patients: A 10-year follow-up cohort study. *Journal of plastic surgery and hand surgery*, <http://eutils.ncbi.nlm.nih.gov/entrez/eutils/elink.fcgi?dbfrom=pubmed&id=23621098&retmode=ref&cmd=prlinks> (2013).
- [33] Newlands LC. Secondary alveolar bone grafting in cleft lip and palate patients. *The British journal of oral & maxillofacial surgery* 2000; 38: 488–491.

- [34] Wong FW, King NM. The oral health of children with clefts--a review. *The Cleft palate-craniofacial journal : official publication of the American Cleft Palate-Craniofacial Association* 1998; 35: 248-54.
- [35] Lin Y-L, Davies K, Callery P. Experience of maintaining tooth brushing for children born with a cleft lip and/or palate. *BMC Oral Health* 2017; 17: 120.
- [36] Quirynen M, Dewinter G, Avontroodt P, et al. A split-mouth study on periodontal and microbial parameters in children with complete unilateral cleft lip and palate. *Journal of clinical periodontology* 2003; 30: 49-56.
- [37] Perdikogianni H, Papaioannou W, Nakou M, et al. Periodontal and microbiological parameters in children and adolescents with cleft lip and /or palate. *International journal of paediatric dentistry / the British Paedodontic Society [and] the International Association of Dentistry for Children* 2009; 19: 455-67.



CHAPTER 4

Midfacial growth and dental arch relationships in bilateral cleft palate following secondary alveolar bone grafting and orthodontic intervention: Factors predicting a Le Fort I osteotomy at age 18

Published in the Journal of Cranio-Maxillofacial Surgery 2018
DOI: 10.1016/j.jcms.2018.07.014

Gerhard KP Bittermann, Adrianus P de Ruiter, Arnold JN Bittermann,
Aebele B Mink van der Molen, Robert JJ van Es, Ron Koole, Antoine JWP Rosenberg

INTRODUCTION

In the Netherlands, congenital disorders are present in 2.2% of all births [1]. Among these, cleft lip and palate (CLP) is one of the most common birth defects. The incidence of all types of CLP in newborns in the Netherlands from 2014 to 2016 decreased from 0.2% in 2014 to 0.19% in 2015 to 0.18% in 2016. The incidence of CLP in European countries ranges between 0.91 and 2.69 of 1000 in all still or live births. The number of newborns with bilateral CLP (BCLP) in the Netherlands in 2014, 2015, and 2016 was 0.025%, 0.016%, and 0.19%, respectively. Briefly, 8-12% of all new CLP cases were bilateral in this time period [2-4]. For unclear reasons the incidence of BCLP in boys is twice that in girls [5, 6].

To date, research on BCLP patients has been scarce. Only a few articles have reported the long-term outcomes of this patient group [7, 8, 9]. Moreover, the number of patients with BCLP has been limited in other previous studies and unilateral CLP and BCLP cases are often combined into a single group [10, 11]. Therefore, specific causes and optimal treatment strategies for BCLP specifically are difficult to discern.

The objectives of BCLP treatment are: good speech, unimpaired growth, a balanced facial morphology, and an optimal dental inter-arch relation [12, 13]. Currently, optimal timing of closures of the soft palate, hard palate, and alveolar process, and the method of bilateral cleft repair remain a subject of debate [9]. Growth potential of unoperated patients with BCLP patients is different from healthy controls [14]. Unoperated patients with BCLP tend to have a protruded maxilla at a later age, which is in contrast to operated patients with BCLP [15, 16, 17].

In general, surgery jeopardizes growth of the facial skeleton, as closure of the soft and hard palate and alveolar bone grafting affect the growth of the midface because of the development of scar tissue and damage to the growth centers [9, 18]. Defining the optimal course and timing of surgical intervention is therefore essential. Primary alveolar bone grafting is defined as bone grafting under 2 years of age [19]. Early secondary alveolar bone grafting (SABG) is carried out before the eruption of the canine or lateral incisor teeth, if present, and late SABG is performed after eruption of the canine teeth [20]. The term tertiary alveolar bone grafting is used in cases where SABG or the osteotomy of the premaxilla, have previously failed. A premaxillary osteotomy (PO) is defined as an osteotomy of the premaxillary segment only in combination with alveolar bone grafting and can be scheduled during early or late SABG [21, 22]. The procedure used in our institute is early and late SABG in combination with a PO [8, 9].

Currently, several methods exist to evaluate facial growth and dental arch relationships, and they can be applied to assess surgical outcomes. The multicenter "Eurocleft study" in Europe evaluated growth of the maxilla and resulted in the development of the GOSLON yardstick [23, 24, 25, 26]. This yardstick was originally used and designed for unilateral cleft patients. Additionally, the GOSLON yardstick has been adapted for the analysis of BCLP; this adaptation has been named the BAURU yardstick [27]. A second method to analyze midfacial growth in patients is cephalometric analysis. This method is commonly used in BCLP evaluations [8, 18].

The present study sought to define predictors of midfacial growth over the course of development using these metrics in patients of the Wilhelmina Children's Hospital (WCH) University Medical Center, Utrecht. The University Medical Center is a tertiary referral center where approximately 7 new BCLP cases are treated annually. We therefore conducted a retrospective analysis of the dental casts of patients with BCLP from 2004 to 2014, who underwent premaxilla osteotomy in combination with bone grafting and evaluated the dental arch relationship and growth potential. The results are compared to the available literature

METHODS

4

Subjects

All files of BCLP patients at the WCH that involved SABG + PO (secondary alveolar bone grafting with PO) between 2004 and 2014 were reviewed, resulting in a total of 70 patients for analyses. Dental casts and lateral cephalograms were obtained preoperatively, postoperatively, and at the end of orthodontic treatment. This patient group has been studied before in a study focusing on other parameters [28].

Medical records were searched for medical history and surgical information, including type and timing of primary surgery, age at surgery, number of secondary surgical procedures, and the presence of post-operative fistulas. All surgeries related to a complication were noted as revision surgery. All patients with BCLP treated between 2004 and 2014 were included. Patients with incomplete medical and/or surgical data or missing dental casts or cephalograms were excluded, resulting in 59 evaluable cases for BAURU analysis and 55 cases for analysis of cephalograms (in four cases the cephalograms were missing).

Surgical protocol

Primary closure of lip, velum, and palate

The surgical protocol involved closure of the lip during the first year of life according to a modified Millard or Tennison technique [29]. In case of wide clefts, lip adhesion was carried out before primary closure of the lip. Closure of the soft palate was carried out by opposing Z-plasty and union of the M. Levator veli palatini, according to the method of Sommerlad, at 1 year of age [30, 31]. The hard palate was closed according to the method of von Langenbeck (1861) at 6 years of age on average (delayed closure) [32]. Regular control of speech was attended to by a speech therapist. A pharyngoplasty was carried out at young age if early speech development was inadequate.

Premaxilla osteotomy and bone grafting

In over 90% of patients, a preoperative orthodontic alignment of the alveolar process was carried out. Orthodontic repositioning of the premaxilla and its teeth was executed, if possible. This was achieved using removable and/or fixed orthodontic appliances for creating

a better preoperative dental front relationship. Closure of the alveolar clefts on both sides of the premaxilla was executed between 8 and 12 years of age with a premaxilla osteotomy. The surgery was planned by mock surgery on a dental cast model, on which a metal splint was fabricated to stabilize the premaxilla. Patients were operated upon with general anesthesia. Patients were administered prophylactic intravenous clindamycin 13 mg/kg three times daily (the normal dose for children) beginning at the start of surgery, until 3 days postoperatively. A premaxilla osteotomy was implemented to create the correct position of the premaxilla and offer better access to the nasal floor for optimal watertight closure of the nasal mucosa. Using this technique, it was possible to reposition the premaxilla in a vertically correct position, preferably in an Angle class I frontal relationship. The premaxilla was fixated apically to the vomerine bone with a 0.4 mm stainless steel wire. Both sides were grafted in one procedure. For grafting, preferably a mandibular symphyseal bone graft was used because of its embryological origin [33, 34]. After premaxilla osteotomy, closure of the nasal layer, and bone grafting, the oral mucosa was closed with slowly resorbable Vicryl 4-0 sutures. The premaxilla was stabilized with a preoperatively fabricated splint. This splint was semi-rigidly fixed with stainless steel wires and acrylic resin. During the first postoperative week, the wound was protected with iodoform-vaseline gauze covered with a zinc oxide-eugenol paste. The metal splint was removed after at least six weeks.

Orthodontic treatment

For new born babies a few weeks after birth pre-surgical palatal plates in the newborns were used only on indication; the indications were feeding difficulties, abnormal tongue thrust and clinically broad cleft. If requested by the speech therapist, orthodontic obturators were rarely used to assist speech in some cases. Removable devices were used for transversal expansion of the dental arch and widening of the cleft if indicated before SABG. Post-operative fixed appliances were used to align the permanent dentition and move the canine or lateral incisor into the bone grafts. Orthognathic surgery was indicated based on the malocclusion of dental arch relationships at 18 years of age (Table 1).

Statistical analyses

Statistical analyses were performed using IBM SPSS Statistics 23 (Statistical Package for the Social Sciences, SPSS Inc. Chicago, IL, USA). Baseline data were assessed, and dependent and independent t tests were used to calculate differences between groups. The correlation between the BAURU scores and cephalometric data was calculated using Pearson's correlation coefficient. Cohen's weighted Kappa was calculated using the Vassarstats calculator $P < 0.05$ was defined as statistically significant [35]. The strength of agreement was defined as poor agreement (Kappa < 0.20), fair (0.21-0.40), moderate (0.41-0.60), good (0.61-0.80), and excellent (0.81-100) [36]. In order to compare our results with other authors' independent t-test results, P values for means and standard deviations (SDs) were calculated using an online calculator (Sauro). Data were plotted using STATA 15 (StataCorp. 2017. Stata Statistical Software: Release 15. College Station, TX: StataCorp LLC).

Table 1. Baseline data

Patients	Included	59	
	Male	37	
	Female	22	
	Mean age		
	Missing	11	5 male, 6 female
		Mean age secondary alveolar bone grafting	12.09 SD 2.017
		Complication	4
Lip closure	Mean age	7.4 months	SD 6.44
Soft palate closure	Mean age	15.8 months	SD 9.65
Hard palate closure	Mean age	5.8 y	SD 2.24
	Before 36 months (N)	6	
	Mean pre-bonegrafting BAURU score <36 months	2.17	SD 0.68
	Men end-point BAURU score < 36 months	2.17	SD 0.82
Secondary alveolar bone grafting	Mean age	11.73 y	SD 1.66
Pre-bonegrafting dental cast	Mean age	10.34 y	SD 2.15
End-point dental cast	Mean age	14.33 y	SD 2.88
Complication		16	
	Missing	1	
Revision surgery		15	
	Missing	1	
Le fort 1 osteotomy	Number of patients	27	45.8%
	Age under 18	9	15.3%
Pharyngeoplasty	Number of patients	13	22%
	Average pre-bonegrafting BAURU score	2.00	
	Average end-point BAURU score	2.46	
No Pharyngeoplasty	Number of patients	46	78%
	Average pre-bonegrafting BAURU score	2.39	
	Average end-point BAURU score	2.59	
Cephalograms	Pre-SABG (N=56)	11.37 y	SD 1.5
	Post SABG (N=56)	11.75 y	SD 1.61
	Long-term (N=53)	15.61 y	SD 2.87

Measurements of dental arch relationship

The selected dental casts were scored using the BAURU yardstick applying the 9-year-old BAURU yardstick scoring system for mixed dentition and 12-year-old BAURU yardstick scoring system for permanent dentition [27]. With BAURU yardstick 4 and 5, orthognathic surgery is expected; BAURU 3 may be treated by orthodontics only; BAURU 1 and 2 are considered a good result for which only minor orthodontic treatment is indicated [23]. All plaster dental casts were collected and patients' pre-SABG + PO and end-point casts were mixed and blindly and randomly scored by two examiners, namely KB (rater 1), a maxillofacial surgery resident, and AdeR (rater 2), an orthodontist. First, the pre-SABG+PO casts were scored without looking at end-point casts, then the end-point model of the same patient was scored. After the first round of examination, results were discussed. The interrater reliability was calculated to prove the reproducibility of the test (Table 2). A score from 1 to 5 according to the BAURU yardstick was given to these casts, 1 representing the best possible result and 5 the worst [27].

Table 2. Interrater correlation using Cohen's Kappa N= 122.

	Weighted Kappa	Standard error of Kappa	95% CI
Rater 1 vs 2	0.76	0.0389	0.684 to 0.836

Rater 1 KB, rater 2 AR; analysis implemented using Vassarstats calculator.

Comparison of BAURU yardstick with other centers

In this study, BAURU scores between the present study and centers of the Bartzela study were compared (Table 3) with centers A, B, and C in Bartzela et al. (2010) corresponding to Gothenburg (Sweden), Nijmegen (the Netherlands), and Oslo (Norway), respectively.

Measurements of the lateral cephalograms

Standardized lateral cephalograms were obtained during the treatment of the patients with BCLP. Among the available cephalograms, the pre-SABG cephalogram, direct post-SABG cephalogram, and the most long-term cephalogram available were selected. If the patient was treated with orthognathic surgery, the pre-Le Fort I cephalogram was analyzed as the longest term cephalogram in this study. The Orthophos XG3® system (Sirona group, Salzburg, Germany) was used for imaging. Each cephalogram was made in a natural head position with teeth in occlusion. The images were exported as a DICOM file and loaded in the analysis software; Viewbox 4.0 (dHal Software®, Athens, Greece, 2014). For analysis, 12 landmarks were determined, which were used to calculate 4 angles. This is a proven method with good inter-observer and intra-observer agreement [38, 39]. For this study, all cephalometric analyses were effected by two raters, KB, a maxillofacial resident, and AR, an experienced maxillofacial surgeon. All landmarks were discussed until consensus. The

cephalometric variables of the pre- and post-SABG + PO and the long-term results were compared to each other. For this study, the BAURU yardstick score and the cephalometric analysis were compared to search for factors predicting a Le Fort I osteotomy at age 18.

Table 3. Comparison of pre-ABG and end-point BAURU-Yardstick data vs. Utrecht using independent t-test.

BAURU-Center	Number of patients	Mean BAURU-Yardstick	SD	95% Confidence interval T-test	P value
Pre-SABG comparison					
A	50	2.37	0.71	-0.3922 to 0.2722	0.72
B	42	2.26	0.45	-0.2504 to 0.3504	0.74
C	112	2.43	0.67	-0.4148 to 0.1748	0.42
Utrecht	59	2.31	1.03		
End-point comparison					
A	40	2.49	0.70	-0.3381 to 0.4781	0.73
B	40	2.72	0.97	-0.6191 to 0.2991	0.49
C	101	2.41	0.71	-0.2224 to 0.5224	0.43
Utrecht	59	2.56	1.33		

There was no significant difference between Utrecht and the centers of the Bartzela et al. (2010) study using Usable stats calculator (Sauro J Usable Stats, 2017); centers A: Gothenburg (Sweden), center B: Nijmegen (the Netherlands), and center C: Oslo (Norway).

RESULTS

Baseline data are reported in Table 1, which details the characteristics of the patient group. Of the 70 consecutive BCLP patients, sufficient suitable dental casts were missing in 11 cases, which resulted in 59 evaluable cases for the dental casts analyses. In 4 of these 59 patients, all lateral cephalograms were lost over time; cephalometric analysis was, therefore, carried out on 55 patients. For comparison of the lateral cephalograms with the BAURU score, only the 55 patients who had both dental casts and cephalograms were analyzed.

BAURU score

Pre-bone grafting dental casts were obtained at a mean age of 10.34 y (SD: 2.15), and end-point dental casts were obtained at a mean age of 14.33 y (SD: 2.88). Both raters scored the pre-SABG + PO and the end-point model of the 59 patients. The mean scores of both raters for the pre-SABG+PO and end-point models trended towards an increase (Figure 1), but failed to show a significant difference in the case of both rater KB ($p=0.071$) and rater AR ($p=0.194$). The mean BAURU score of the two raters was used to compare the pre-SABG+PO and end-point models, which did not show a significant difference ($p=0.099$).

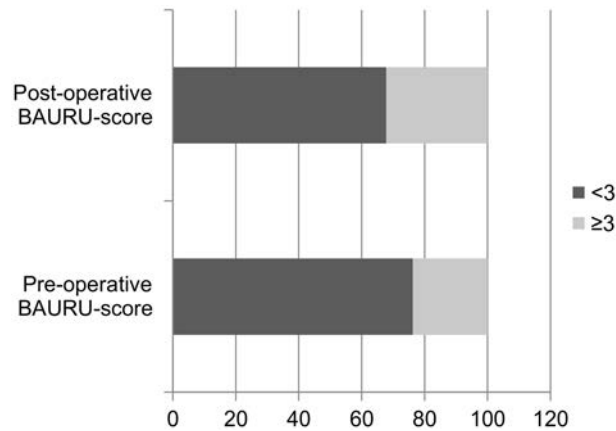


Figure 1. Clinically relevant BAURU scores.

The clinical relevance is present in Table 4 and Figure 1: the grey cells demonstrate unchanged BAURU scores after SABG and premaxilla osteotomy. The numbers *below* the grey line demonstrate a deterioration after SABG. In Figure 1, the scores were divided into two groups, BAURU below 3 and BAURU equal to three and higher (Figure 1). The reason that the cut-off point of 3 was placed in groups 4 and 5 was that a score of 3 may be considered borderline for orthodontic treatment only.

The correlation between age at surgery and the increase of the BAURU score was investigated using linear regression, and did not show a significant correlation. Linear regression did show a significant ($p=0.00$) correlation, with the cofactor “preoperative score” being correlated with the post-operative score (Table 5). In other words, the procedure of SABG+PO itself does not seem to influence the postoperative BAURU score. However, according to our findings, a poor preoperative score is predictive for a poor postoperative outcome at age 14.3 yr.

Interrater agreement

The interrater agreement for the BAURU yardstick was 0.76 weighted Kappa, representing a good correlation between raters (Table 2).

Cephalometric analyses and correlations between cephalometric analysis and BAURU scores

The angles for SNA, SNB, ANB, and upper incisor to palatal plane with means and SDs were calculated for included patients (Figure 2, Table 6). Correlations between BAURU scores and cephalometric data were calculated using the Pearson’s correlation. Negative correlations were found between: the pre-SABG+PO ANB angle and the pre-SABG+PO BAURU scores ($R=-0.58$ $P=0.000$); the long term post-SABG+PO ANB and the mean end-point BAURU ($R=-$

Table 4. Comparison of BAURU yardstick scores rater 1 and 2.

		Pre-ABG score					
		BAURU 1	BAURU 2	BAURU 3	BAURU 4	BAURU 5	Total
Rater 1							
End-point	BAURU 1	8	2	1	0	0	11
	BAURU 2	3	12	6	2	1	24
	BAURU 3	2	4	1	1	0	8
	BAURU 4	1	2	1	0	2	6
	BAURU 5	0	3	4	3	0	10
	Total	14	23	13	6	3	59
Rater 2							
		Pre-ABG score					
		BAURU 1	BAURU 2	BAURU 3	BAURU 4	BAURU 5	Total
End-point	BAURU 1	7	5	1	1	0	14
	BAURU 2	3	20	2	1	0	26
	BAURU 3	0	6	0	0	0	6
	BAURU 4	0	2	0	1	1	4
	BAURU 5	0	2	2	3	2	9
	Total	10	35	5	6	3	59

The gray cells demonstrate the BAURU scored that did not change after SABG and premaxilla osteotomy. The numbers below the gray line demonstrate a worse outcome after SABG and premaxilla osteotomy.

0.50 $p=0.000$); and the pre-SABG+PO ANB and the mean end-point BAURU ($R=-0.51$ $p=0.000$) (Table 7). The cephalometric analyses were divided according to $BAURU < 3$ and $BAURU \geq 3$ (Figure 1), and means of the cephalometric analysis were calculated for both groups (Table 8). A correlation was seen between pre-SABG ANB angle and the end-point BAURU score. A histogram was created and a cutoff point (ANB 6 degrees) was calculated using the intersection of the two groups (Figure 3). If the pre-SABG+PO (mean age 11.36 years) ANB was below 6 there was a 78% chance that a Le Fort 1 osteotomy was required by the age of 18 (Table 8).

Comparison with other centers using the study by Bartzela et al. (2010)

The age-groups of 9 and 12 years were used for comparison, as both studies included this age group. There were no significant differences between the BAURU scores of each center in Bartzela et al. (2010) and the scores for our patients at WCH, Utrecht. Overall, there appeared to be a trend towards a slight deterioration of the BAURU scores before and after SABG+PO beginning at 10 years of age (Table 3).

Table 5. Effect of age on surgery and pre-operative score, with the post-operative score as reference using linear regression.

Variable	P-value	Estimate	95% CI
Age on surgery date	0.50	0.062	-0.120 to 2.44
Pre-bonegrafting BAURU score	0.00*	0.68	0.38 to 0.97

* Significant effect of the pre-bonegrafting score on the end-point score.

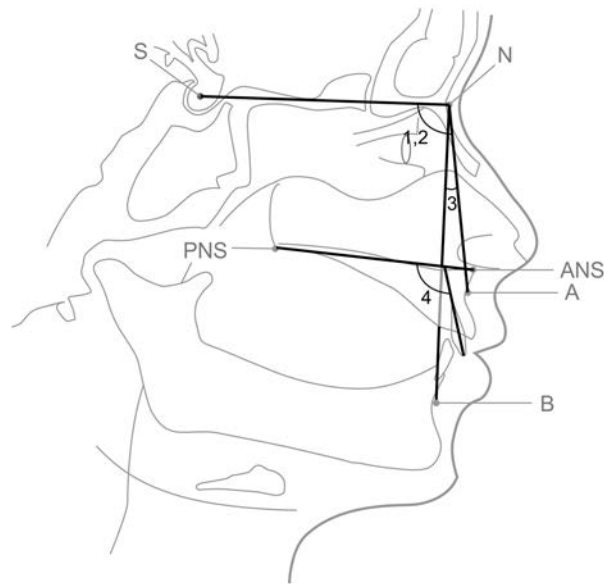


Figure 2. Cephalometric points and angles. The figure is adjusted with permission from Paes et al. (2016). 1=SNA, 2=SNB, 3=ANB, 4=Upper incisor tot palatal plane.

Table 6. Cephalometric values.

Variable	Mean	Number of patients
All patients		
Pre-SABG SNA	81.99 (70.7–92.9)	55
Pre-SABG SNB	74.86 (67.3–84.1)	55
Pre-SABG ANB	7.13 (-3.4–16.1)	55
Pre-SABG upper incisor to palatal plane	86.47 (58.1– 121)	55
Post-SABG SNA	79.159 (68.3–89.6)	54
Post-SABG SNB	74.972 (66.5–85.2)	54
Post-SABG ANB	4.174 (-4.3–13.4)	54
Post-SABG upper incisor to palatal plane	96.970 (73.4–124.4)	54
Long term SNA	77.020 (66.1–88.4)	51
Long term SNB	75.898 (67.2–85.1)	51
Long term ANB	1.112 (-9–9.6)	51
Long term upper incisor to palatal plane	103.308 (72.0–140.6)	51
BAURU endpoint 1, 2 subgroup		
Pre-SABG SNA	81.90 (70.7–92.8)	37
Pre-SABG SNB	73.58 (67.3–82.8)	37
Pre-SABG ANB	8.32 (-0.9–16.1)	37
Pre-SABG upper incisor to palatal plane	85.44 (58.1–12.1)	37
Post SABG SNA	78.78 (68.3–87.1)	36
Post SABG SNB	73.67 (66.5–81.4)	36
Post SABG ANB	5.11 (-1.8–12.1)	36
Post SABG upper incisor to palatal plane	96.69 (73.4–124.4)	36
Long term SNA	77.13 (66.1–88.4)	35
Long term SNB	75.02 (67.2–84.3)	35
Long term ANB	2.10 (-3.7–9.6)	35
Long term upper incisor to palatal plane	105.35 (78.0–140.6)	35
BAURU endpoint 3-5 subgroup		
Pre-SABG SNA	82.16 (72.4–91.6)	18
Pre-SABG SNB	77.47 (67.9–84.1)	18
Pre-SABG ANB	4.7 (67.9–84.1)	18
Pre-SABG upper incisor to palatal plane	88.589 (65.9–121.0)	18

Table 6. Continued

Variable	Mean	Number of patients
Post-SABG SNA	79.91 (70.4–89.6)	18
Post SABG SNB	77.58 (66.6–85.2)	18
Post SABG ANB	2.31 (-4.3–13.4)	18
Post SABG upper incisor to palatal plane	97.53 (78.2–118.9)	18
Long term SNA	76.78 (67.5–84.8)	16
Long term SNB	77.81 (69.1–85.1)	16
Long term ANB	-1.04 (-9.0–4.2)	16
Long term upper incisor to palatal plane	98.83 (72.0–120.1)	16

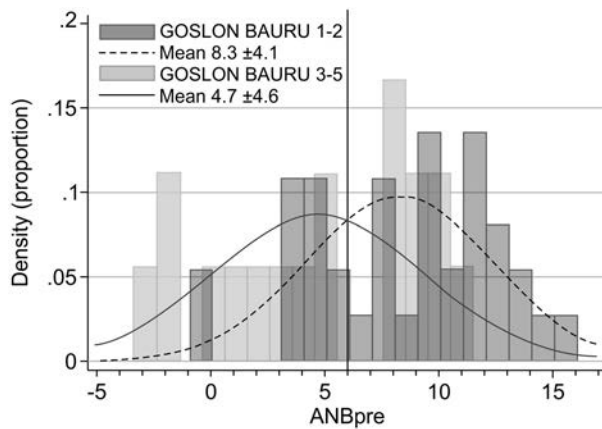


Figure 3. Relationship of the pre-ANB scores and long-term postoperative BAURU-scores. The interception of the groups (BAURU 1-2 vs. 3-5) represents the cutoff point of ANB in our patient group.

DISCUSSION

To the best of our knowledge this is the largest set of SABG + PO long term outcome data described in literature. However, there is a study of this same group of patients that has not been published which focuses on the complications of the SABG+PO procedure [28]. The present study evaluated the growth after SABG+PO in a large group of patients with BLCP in order to identify prognostic factors for growth. After evaluating pre-SABG+PO and end-point dental arch relationships, we did not find a significant difference in the maxillary growth potential in patients with BLCP after SABG+PO in our patient group. However, there was a slight, though insignificant, trend towards inhibition of growth represented by a slight

Table 7. Significant correlations between BAURU scores and cephalometric values.

Variable	R value	P value (Pearson's correlation)
Pre-SABG SNA vs. Pre-SABG BAURU	-0.285	0.035*
Pre-SABG ANB vs. Pre-SABG BAURU	-0.58	0.000***
Pre-SABG ANB vs. Endpoint mean BAURU	-0.51	0.000***
Long term post SABG ANB vs. end-point mean BAURU scores	-0.501	0.000***

*p < 0.05, **p < 0.01, ***p < 0.001.

Table 8. Pre-SABG ANB vs. end-point BAURU score.

Pre-SABG ANB < 6	Number of patients	22
	Mean end-point BAURU	3.14 (SD 1.63)
	Mean post SABG ANB	1.33 (SD 2.87)
	Mean long-term ANB	- 1.65 (SD 3.28)
	Le Fort 1 osteotomy	Yes: 14 (63.6%) No: 4 (18.2%) Under 18: 4 (18.2%)
	Le Fort 1 < 18 years long term ANB	-0.5 (SD 2.7)
Pre-SABG ANB ≥ 6	Number of patients	33
	Mean end-point BAURU	2.24 (SD 1.00)
	Mean post SABG ANB	6.00 (SD 3.33)
	Mean long-term ANB	3.05 (SD 2.85)
	Le Fort 1 osteotomy	Yes: 12 (36.4%) No: 17 (51.5%) Under 18: 4 (12.1%)
	Le Fort 1 < 18 years long term ANB	4.7 (SD 1.75)

deterioration of the BAURU scores in the course of the second decade of life. This is supported by measurements from the lateral cephalograms, which demonstrated a slight decrease of the SNA and ANB angle after 10 years of age, indicating slower midfacial growth. Our analysis shows a decrease of the ANB angle over time with a normal SNB angle, meaning a decrease of growth of the maxilla compared to an unimpaired growth of the mandible. This was also reported by Geraedts et al. (2007) in their analysis of 40 BCLP patients treated with SABG and PO [8].

In the present study, the BAURU scores and the cephalometrics were compared, and demonstrated a significant negative correlation between the pre-SABG ANB and the end-

point BAURU scores. To the best of our knowledge, the combination of these two findings as a predictor for later midfacial growth impairment has never been described before. First, this important information may be used to inform the patients on the future surgery, i.e. Le Fort I osteotomy. Secondly, if a ANB angle of < 6 degrees is found, it is important to stop orthodontic treatment, and reschedule orthodontics one year before the actual Le Fort I osteotomy. This strategy may prevent extremely long lasting orthodontic treatments during patients' childhood. However, it is important to point out that this predictor may only be used in a group of patients with a treatment protocol similar to the protocol used in the present study. In keeping with our results, a negative correlation between ANB and GOSLON scores in unilateral patients with CLP was already reported [40, 41]. Such treatment/disease-type-specific data are essential, as it is important to be able to predict the midfacial growth and the outcome based on the treatment protocol in order to predict the surgery needed to achieve the best outcome. This is especially the case in patients with BCLP for whom the need for Le Fort I osteotomies is high [42].

In the present study, the dental arch relationship of patients with BCLP was analyzed at two time points: pre-SABG with mixed dentition and after approximately two decades (the end-point), when there was permanent dentition and an interval in the orthodontic treatment. These data were compared to the only other known long-term study of BCLP [10]. Comparing our findings to these other centers did not demonstrate significant differences.

The BAURA yardstick is a valuable system to review sagittal growth, because the sagittal skeletal dimension is the most important factor if the BAURU yardstick is used to score dental casts in patients with BCLP. Moreover, in applying the BAURU yardstick in this study, the inter-rater reliability in this study was high and comparable with previous studies [38, 42, 43]. The BAURU scores in the present study were compared to the scores of Bartzela et al. (2010). No significant differences were found between the BAURU yardstick scores at the age groups of 9 and 12 years and the data presented by Bartzela et al. (2010). Additionally, no significant differences were found between the older age groups between centers included in the Bartzela study and the older age groups in our study. We also did not find a significant difference between the pre-SABG+PO and end-point BAURU scores, and that most patients starting with a high BAURU-score will retain a high BAURU score.

Nevertheless, there was a non-significant increase in the BAURU scores (Table 4 and in Figure 1). This increase in BAURU score was also found in the samples of the Bartzela study and may indicate that the effect on growth is not solely a result of surgical interventions in BCLP patients. Thus, growth potential of the maxilla may be affected by other factors. This finding is in accordance with the findings by Geraerds et al. (2007); they compared their treatment protocol including a premaxilla osteotomy to the Oslo treatment protocol without a premaxilla osteotomy [8, 10]. The patients with premaxilla osteotomy showed a more convex profile compared to the Oslo patients without premaxilla osteotomy [10].

If there were effects on growth of the mid-face, one would expect a retrusive concave mid-face in patients after a premaxilla osteotomy [44]. Age at time of SABG+PO did not show any effect on the end-point BAURU scores we measured. This is in accordance with the study

of Bartzela et al. (2010). The present study analyzed the face profile using cephalometric images, and our data shows that there is no significant catch-up growth visible, as most patients who start with a retrusive profile will end with a retrusive profile.

In our study, infant orthopedics was only used if there were any feeding or speech difficulties in the patients. Bartzela et al. (2010) reported on the use of infant orthopedics in Nijmegen and Gothenburg patients. After completion of treatment, there was no significant difference between infants with and without infant orthopedics. Indeed, these devices can have a short-term effect on growth; however, eventually, there is no noticeable effect on growth [45].

It is expected that delayed closure of the hard-palate is beneficial for the growth of the maxilla and should result in a better BAURU-score at the end of the treatment protocol. However, Bartzela et al. (2010) did not see a difference between centers A and B in carrying out delayed closure compared to center C (Oslo), which used early closure [12]. In the present study, 6 patients had hard palatal closure before 36 months with mean end-point BAURU scores of 2.16, which is considered a good result.

In a study done by our cleft team on unilateral patients compared to other centers with different protocols, it was found that not only the timing of palate closure is important, but also the technique might be a factor [46]. Looking at the timing of surgery there is only one randomized controlled trial study of treatment of unilateral cleft lip and palate patients on delayed closure of the palate; they found no difference for dental arch relationship in the delayed closure group compared to the early group [47]. Besides the technique and the timing of the surgery in patients with BCLP, another factor contributing to growth impairment in CLP is genetic profile. However, the genetics of cleft lip and palate patients remain somewhat unclear [48, 49]. Indeed, this question is difficult as highlighted by the findings of Honda et al. (1995) that especially in patients with BLCP there is no detectable growth pattern due to congenital absence of nasomaxillary tissue and the intrinsic and genetically-influenced growth pattern of each individual [50].

Limitations

Because this a retrospective study, some data were lost over time. Moreover, this was a single center study, meaning that correlations found are only applicable to groups of patients with the same treatment protocol as in our hospital.

CONCLUSION

In this study of 55 BCLP patients treated with SABG+PO, no differences were found between the pre-SABG+PO BAURU and end-point BAURU scores. There was a decrease in SNA and ANB angle over time, indicating a delayed growth of the maxilla. A negative correlation between the pre-SABG ANB and end-point BAURU score was demonstrated, enabling clinicians to predict the midfacial growth and need for Le Fort I osteotomy until the patients are fully grown at age 18. Surgery is sometimes considered a main growth inhibiting factor


in the treatment of patients with BCLP. Comparison of surgical protocols in ours and other studies cited herein revealed similar BAURU end scores. Our findings suggest that SABG+PO surgery is not a clinically relevant midfacial growth inhibiting factor in patients with BCLP, but prospective studies are needed for confirmation.

REFERENCES

- [1] Schönbeck Y, Hindori-Mohangoo AD, Masurel N, et al. Aangeboren afwijkingen in Nederland 2001-2013: Gebaseerd op de landelijke perinatale registraties. 2015; 72.
- [2] Luijsterburg AJM, Trenning AH, Ongkosuwito EM, et al. NVSCA-REGISTRATIE SCHISIS JAARVERSLAG 2014 Nederlandse teams Nederlandse Vereniging voor Schisis en Craniofaciale Afwijkingen. 2014; 1-21.
- [3] Luijsterburg AJM, Trenning AH, Ongkosuwito EM, et al. NVSCA-REGISTRATIE SCHISIS JAARVERSLAG 2015 Nederlandse teams Nederlandse Vereniging voor Schisis en Craniofaciale Afwijkingen. 2015; 1-21.
- [4] Luijsterburg AJM, Trenning AH, Ongkosuwito EM, et al. NVSCA-REGISTRATIE SCHISIS JAARVERSLAG 2016 Nederlandse teams Nederlandse Vereniging voor Schisis en Craniofaciale Afwijkingen. 2016; 1-21.
- [5] Kouwenberg M, Draaisma Jmt, Kuijpers-Jagtman A, et al. Bijkomende aangeboren aandoeningen bij een complete dubbelzijdige cheilognathopalatoschisis. *Tijdschrift Kindergeneeskunde* 2010; 78: 15-20.
- [6] Adrichem V. Lip-kaak- en gehemelte spleten in Nederland. *Nederlands tijdschrift voor plastische chirurgie* 2013; 11-18.
- [7] Heidbuchel KL, Kuijpers-Jagtman a M, Freihofer HP. An orthodontic and cephalometric study on the results of the combined surgical-orthodontic approach of the protruded premaxilla in bilateral clefts. *Journal of crano-maxillo-facial surgery : official publication of the European Association for Cranio-Maxillo-Facial Surgery* 1993; 21: 60-6.
- [8] Geraedts CTM, Borstlap WA, Groenewoud JMM, et al. Long-term evaluation of bilateral cleft lip and palate patients after early secondary closure and premaxilla repositioning. *International Journal of Oral and Maxillofacial Surgery* 2007; 36: 788-796.
- [9] Bittermann GKP, de Ruiter AP, Janssen NG, et al. Management of the premaxilla in the treatment of bilateral cleft of lip and palate: what can the literature tell us? *Clinical Oral Investigations*. Epub ahead of print 2015. DOI: 10.1007/s00784-015-1589-y.
- [10] Bartzela T, Katsaros C, Shaw WC, et al. A longitudinal three-center study of dental arch relationship in patients with bilateral cleft lip and palate. *The Cleft palate-craniofacial journal : official publication of the American Cleft Palate-Craniofacial Association* 2010; 47: 167-174.
- [11] Harila V, Ylikontiola LP, Sándor GK. Dental arch relationships assessed by GOSLON Yardstick in children with clefts in Northern Finland. *European journal of paediatric dentistry : official journal of European Academy of Paediatric Dentistry* 2014; 15: 389-391.
- [12] Nollet PJPM, Katsaros C, Van't Hof MA, et al. Treatment outcome in unilateral cleft lip and palate evaluated with the GOSLON yardstick: a meta-analysis of 1236 patients. *Plastic and reconstructive surgery* 2005; 116: 1255-62.
- [13] Lisson JA, Hanke I, Tränkmann J. Changes of vertical skeletal morphology in patients with complete unilateral and bilateral cleft lip and palate. *Cleft Palate-Craniofacial Journal* 2005; 42: 490-494.
- [14] Semb G, Shaw WC. Cleft Lip and Palate. Epub ahead of print 2013. DOI: 10.1007/978-3-642-30770-6.
- [15] Mars M, Houston WJB. A preliminary study of facial growth and morphology in unoperated male unilateral cleft lip and palate subjects over 13 years of age. *Cleft Palate Journal* 1990; 27: 7-10.
- [16] Capelozza Jr. L, Taniguchi SM, da Silva Jr. OG. Craniofacial morphology of adult unoperated complete unilateral cleft lip and palate patients. *Cleft Palate-Craniofacial Journal* 1993; 30: 376-381.
- [17] Filho LC, Normando ADC, da Silva Filho OG. Isolated influences of lip and palate surgery on facial growth: Comparison of operated and unoperated male adults with UCLP. *Cleft Palate-Craniofacial Journal* 1996; 33: 51-56.

- [18] Semb G. A study of facial growth in patients with bilateral cleft lip and palate treated by the Oslo CLP Team. *The Cleft palate-craniofacial journal : official publication of the American Cleft Palate-Craniofacial Association* 1991; 28: 22–39; discussion 46–8.
- [19] Vyas RM, Kim DC, Padwa BL, et al. Primary premaxillary setback and repair of bilateral complete cleft lip: Indications, technique, and outcomes. *Cleft Palate-Craniofacial Journal* 2016; 53: 302–308.
- [20] Freihofer HPM, Borstlap WA, Kuijpers-Jagtman AM, et al. Timing and transplant materials for closure of alveolar clefts. A clinical comparison of 296 cases. *Journal of Cranio-Maxillofacial Surgery* 1993; 21: 143–148.
- [21] Freihofer HPM, van Damme PA, Kuijpers-Jagtman AM. Early secondary osteotomy-stabilization of the premaxilla in bilateral clefts. *Journal of Cranio-Maxillofacial Surgery* 1991; 19: 2–6.
- [22] Dempf R, Teltzrow T, Kramer FJ, et al. Alveolar bone grafting in patients with complete clefts: a comparative study between secondary and tertiary bone grafting. *Cleft Palate Craniofac J* 2002; 39: 18–25.
- [23] Mars M, Plint DA, Houston WJ, et al. The Goslon Yardstick: a new system of assessing dental arch relationships in children with unilateral clefts of the lip and palate. *The Cleft palate journal* 1987; 24: 314–22.
- [24] Shaw WC, Semb G, Nelson P, et al. The Eurocleft project 1996–2000: overview. *J Craniomaxillofac Surg* 2001; 29: 131–132.
- [25] S. H, M.K. A, a.I. A. An overview of indices used to measure treatment effectiveness in patients with cleft lip and palate. *Malaysian Journal of Medical Sciences* 2015; 22: 4–11.
- [26] Mølsted K, Brattström V, Prah Andersen B, et al. The Eurocleft study: intercenter study of treatment outcome in patients with complete cleft lip and palate. Part 3: dental arch relationships. *The Cleft palate-craniofacial journal : official publication of the American Cleft Palate-Craniofacial Association* 2005; 42: 78–82.
- [27] Ozawa TO, Shaw WC, Katsaros C, et al. A new yardstick for rating dental arch relationship in patients with complete bilateral cleft lip and palate. *The Cleft palate-craniofacial journal : official publication of the American Cleft Palate-Craniofacial Association* 2011; 48: 167–172.
- [28] Bittermann GKP, van Es RJJ, de Ruiter AP, et al. Incidence of complications in secondary alveolar bone grafting of bilateral clefts with premaxillary osteotomy: a retrospective cohort study. *Clinical Oral Investigations* 2020; 24: 915–925.
- [29] Millard D. Complete Unilateral Clefts of the Lip. *Plastic and reconstructive surgery* 1960; 25: 595–605.
- [30] Furlow LT. Cleft palate repair by double opposing Z-plasty. *Plastic and reconstructive surgery* 1986; 78: 724–38.
- [31] Sommerlad BC. A technique for cleft palate repair. *Plastic and Reconstructive Surgery* 2003; 112: 1542–8.
- [32] von Langenbeck B. Operation der angeboren totalen Spaltung des harten Gaumens nach einer neuen Methode. *Drsch Klin* 1861; 8: 231.
- [33] Koole R. Ectomesenchymal mandibular symphysis bone graft: An improvement in alveolar cleft grafting? *Cleft Palate-Craniofacial Journal* 1994; 31: 217–223.
- [34] Koole R, Bosker H, van der Dussen FN. Late secondary autogenous bone grafting in cleft patients comparing mandibular (ectomesenchymal) and iliac crest (mesenchymal) grafts. *J Craniomaxillofac Surg* 1989; 17 Suppl 1: 28–30.
- [35] Lawry Richard. Vassarstats. 06-09-2017, <http://vassarstats.net/kappa.html>.
- [36] Landis JR, Koch GG. The Measurement of Observer Agreement for Categorical Data. *Source: Biometrics BIOMETRICS* 1977; 3312123973: 159–174.

- [37] Sauro J. Usable Stats. 06-09-2017, <http://www.usablestats.com/calcs/2sample&summary=1>.
- [38] Kappen IFPM, Bittermann GKP, Schouten RM, et al. Long-term mid-facial growth of patients with a unilateral complete cleft of lip, alveolus and palate treated by two-stage palatoplasty: cephalometric analysis. *Clinical Oral Investigations*. Epub ahead of print 2016. DOI: 10.1007/s00784-016-1949-2.
- [39] Paes EC, Bittermann GKP, Bittermann D, et al. Long-Term Results of Mandibular Distraction Osteogenesis with a Resorbable Device in Infants with Robin Sequence. *Plastic and Reconstructive Surgery* 2016; 137: 375e–385e.
- [40] Daskalogiannakis J, Mercado A, Russell K, et al. The americleft study: An inter-center study of treatment outcomes for patients with unilateral cleft lip and palate part 3. Analysis of craniofacial form. *Cleft Palate-Craniofacial Journal* 2011; 48: 252–258.
- [41] Suzuki A, Sasaguri M, Hiura K, et al. Can occlusal evaluation of children with unilateral cleft lip and palate help determine future maxillofacial morphology? In: *Cleft Palate-Craniofacial Journal*, pp. 696–706.
- [42] Voshol IE, van der Wal KGH, van Adrichem LNA, et al. The frequency of Le Fort I osteotomy in cleft patients. *Cleft Palate-Craniofacial Journal* 2012; 49: 160–166.
- [43] Mueller AA, Zschokke I, Brand S, et al. One-stage cleft repair outcome at age 6- to 18-years -- a comparison to the Eurocleft study data. *The British journal of oral & maxillofacial surgery* 2012; 50: 762–768.
- [44] Heidbüchel K, Kuijpers-Jagtman A, Freihofer H. Facial growth in patients with bilateral cleft lip and palate: a cephalometric study. *Cleft Palate Craniofac J* 1994; 31: 210–215.
- [45] Bongaarts CAM, van 't Hof MA, PrahI-Andersen B, et al. Infant orthopedics has no effect on maxillary arch dimensions in the deciduous dentition of children with complete unilateral cleft lip and palate (Dutchcleft). *The Cleft palate-craniofacial journal: official publication of the American Cleft Palate-Craniofacial Association* 2006; 43: 665–672.
- [46] Kappen IFPM, Bittermann GKP, Bitterman D, et al. Long-term follow-up study of patients with a unilateral complete cleft of lip, alveolus, and palate following the Utrecht treatment protocol: Dental arch relationships. *Journal of Cranio-Maxillofacial Surgery* 2017; 1–6.
- [47] Rautio J, Andersen M, Bolund S, et al. Scandcleft randomised trials of primary surgery for unilateral cleft lip and palate: 2. Surgical results. *Journal of Plastic Surgery and Hand Surgery* 2017; 51: 14–20.
- [48] Leslie EJ, Marazita ML. Genetics of cleft lip and cleft palate. *American Journal of Medical Genetics, Part C: Seminars in Medical Genetics* 2013; 163: 246–258.
- [49] Ludwig KU, Hoebel AK, Drichel D, et al. of Dental ResearchCandidate Genes for Nonsyndromic Cleft Palate Detected by Exome Sequencing Candidate Genes for Nonsyndromic Cleft Palate Detected by Exome Sequencing. *Journal of Dental Research* 2017; 96: 1314–1321.
- [50] Honda Y, Suzuki A, Ohishi M, et al. Longitudinal Study on the Changes of Maxillary Arch Dimensions in Japanese Children with Cleft Lip and/or Palate: Infancy to 4 Years of Age. *The Cleft Palate-Craniofacial Journal* 1995; 32: 149–155.



CHAPTER 5

Retrospective analysis of clinical outcomes in bilateral cleft lip and palate patients after secondary alveolar bone grafting and premaxilla osteotomy using a new Dento-Maxillary Scoring System

Published in Journal of Cranio-Maxillofacial surgery 2020
DOI: 10.1016/j.jcms.2020.12.006

Gerhard KP Bittermann, Robert JJ van Es, Adrianus P de Ruiter, Arnold JN Bittermann, Ron Koole, Antoine JWP Rosenberg

INTRODUCTION

The treatment of patients with cleft lip and palate is planned and executed to achieve an acceptable end result in which stigmata are corrected to produce a balanced symmetrical face with harmonic proportions. One of the end points in cleft care is an orthognathic relationship with a complete dental arch, which contributes to both aesthetics and function [1]. To achieve such for patients with bilateral cleft lip and palate (BCLP), correct timing of the secondary alveolar bone grafting (SABG) procedure, which may be combined with a premaxillary osteotomy (PMO), is important. Successful bone grafting facilitates dental rehabilitation with the patient's dentition or with a fixed prosthesis [2]. The timing of the procedure is chosen to support successful eruption of the canine or lateral incisor into the bone graft and therefore to reduce the risk of the development of complications at the end of growth [3, 4]. The reason for carrying out a SABG+PMO procedure is not only the support of teeth or dental implants: the treatment is also executed to stabilise the alveolar ridge, to provide bony support and favourable periodontal health to the adjacent teeth of the alveolar cleft, to facilitate eruption of the impacted canine, to close residual oro-nasal fistulas and to support the alar base of the nose. All these factors are addressed through application of the SABG+PMO procedure [5]. Residual bone height after the execution of SABG+PMO procedures is important to achieve a complete dental arch [6–8]. Early SABG+PMO, achieved in patients before the age of 10, yields the best results in residual bone height and the ability to guide the canine into the bone graft [4, 9, 10, 11]. If a tooth adjacent to the cleft is absent or hypoplastic, closure of the diastema can be executed by moving adjacent teeth orthodontically into the dental gap, by means of a segmental osteotomy of the small fragment, by auto-transplantation of redundant teeth in the grafted cleft area or with prosthodontics, e.g. through use of an adhesive bridge or a dental implant [12, 13, 14]. The sagittal dental relationship at the end of the treatment period makes an important contribution to the stigmata of patients with cleft lip and palate. About 30–50% of these patients have maxillae in retruded position, which can be an indication of the need for a maxillary advancement osteotomy or distraction [15, 16]. In an earlier study, a maxilla osteotomy was indicated in 46% of patients with BCLP [17]. Literature reports that a favourable end result in BCLP treatment requires approximately five to eight surgeries with general anaesthesia [18]. In the Department of Oral and Maxillofacial Surgery of the Wilhelmina Children's Hospital at the University Medical Centre Utrecht in The Netherlands (WCH cleft team Utrecht), patients have been treated by the cleft team through lip closure, soft-palate closure, hard-palate closure, removal of deciduous teeth in the cleft area, SABG with PMO and if necessary a pharyngoplasty or (bi)maxillary osteotomy. Finally, an optional secondary rhinoplasty has been added if desirable. In literature, various scoring systems are described that assess outcomes after cleft lip and palate surgery with respect to overall facial morphology or specific parts of facial morphology, e.g. the BAURU Yardstick, by which the development of the maxilla and its relation to the mandible are scored [19, 20, 21]. The diseased, missing or filled teeth (DMFT)

scoring method is a system in which the dental situation is classified [22]. There are various questionnaires that cover mastication and oral health, by which the patient's perspective can be measured. These scoring systems cover small and different items that cover the outcome of cleft lip palate care. More recently, 3D imaging and analysis has also become an important method for analysis of post-operative results. The present article aims to present a method that covers all aspects of the dento-maxillary rehabilitations and can be obtained with available clinical and radiological data, giving a simple overall score.

In this retrospective study at the WCH cleft team Utrecht, the end results of treatment of patients with BCLP were analysed. It was of special interest if an orthognathic maxillary relationship with an uninterrupted dental arch was established. The study was effected on patients with BCLP who had undergone SABG+PMO and orthodontic treatment and eventually prosthodontic rehabilitation.

A practical Dento-Maxillary Scoring System (DMSS0 is proposed to evaluate the clinical outcomes at the end of BCLP treatment.

MATERIALS AND METHODS

This study is a retrospective consecutive cohort study of all children with complete BCLP who underwent SABG+PMO at the WCH Utrecht between 2004 and 2014. The study was executed at the end of follow-up at our institution. Secondary rhinoplasties were performed after the maxillo-facial rehabilitation and therefore this procedure was part of this analysis. Treatment consisted of SABG+PMO and was timed at 2/3 developmental stage of the root of the maxillary canine or the lateral incisor if present. Patients were aged between nine and 13 years.

Primary closure

Patients had been treated according the surgical BCLP protocol, which involved closure of the lip at approximately six months of age according to a modified Millard or Tennison technique [23]. Closure of the soft palate had been accomplished according to the procedure described by Sommerlad at seven to nine months of age [24]. Closure of the hard palate had been carried out as described by von Langenbeck at three to six years of age, with the modification that the palatal flaps were dissected epiperiosteally [25]. The treatment protocol is visualised in Table 1.

Orthodontic protocol before and after SABG +PMO

As there were no defects in the mandible, the orthodontic treatment was started with the creation of a mandibular dental arch, by means of fixed appliances between the ages of nine and 11 years, dependent on the timing of the grafting operation. Prior to the SABG+PMO, a short interceptive orthodontic expansion procedure of the maxillary arch was completed with Quad-Helix devices or removable appliances. A Quad-Helix was chosen

Table 1. Treatment protocol

Age	Procedure
Six months	Closure of lip (Millard, Tennison)
Seven – nine months	Closure of soft palate (Sommerlad)
Three - six years	Closure of hard palate (Langenbeck)
Six – nine years	Pharyngoplasty if necessary
Nine – 13 years	Secondary alveolar bonegrafting with premaxilla osteotomy
18 years	Orthognathic surgery if necessary
20 years or above	Secondary rhinoplasty if necessary

in a bilateral transversal crossbite, removable appliances were chosen in cases of an unilateral crossbite or a frontal crossbite. This expansion was necessary not only to enlarge the operating area and to facilitate access to it, but also to determine the future intermaxillary transverse relationship. Additionally, the aim of this procedure was to position the premaxilla in a positive sagittal overbite and overjet to the mandibular arch, if possible. About two to three months after SABG+PMO, a final long-term active orthodontic treatment took place to create correct dental intra- and inter-arch relationships. Two orthodontists carried out all orthodontic treatments with full fixed appliances. The bone in the cleft was functionally loaded by moving adjacent teeth into the bone graft to ensure the bone continuity of the newly-created alveolar ridge. After completion of the orthodontic treatment, the maxillary and mandibular front teeth were retained permanently from canine to canine with bonded retainers. Additionally, the transversal expansion of maxillary arch was retained with a removable appliance, to be worn at night life time by the patient .

Surgical protocol SABG+PMO

Planning involved mock surgery on a dental cast model, on which a custom metal splint was pre-bent and soldered over the dental cast model to stabilise the premaxilla. Surgery was done with the use of general anaesthesia. Prophylactic intravenous clindamycin 13 mg/kg was administered at the start of surgery and continued three times daily for three days postoperatively. A PMO was carried out to correct the position of the premaxilla and to improve access to the nasal floor for watertight closure of the nasal mucosa. The premaxilla was replaced in a positive sagittal overjet and overbite, and then fixated apically to the vomerine bone with a 0.4 mm stainless steel wire. After fixation of the premaxilla, the nasal layer was closed, and the premaxilla fixated with the metal splint. Both sides were grafted in one procedure. For grafting, preferably a mandibular symphyseal bone graft was used; if this was not possible, because of insufficient bone or anatomical variations, an iliac crest graft was used. After bone grafting, the oral mucosa was closed with slowly resorbable Vicryl 4-0 sutures. During the first postoperative week, the wound was protected with iodoform-vaseline gauze covered with a zinc oxide-eugenol paste. The metal splint was removed after six weeks.

Prosthetic protocol

In patients with BCLP, lateral incisors are frequently absent or hypoplastic. In these cases, they may be removed during the SABG+PMO procedure. In cases where teeth are missing, an interrupted maxillary arch in good relationship with the mandible is a prerequisite for prosthetic replacement of teeth. If sufficient bone is present, it is preferable to move canines orthodontically and even (pre)premolars mesially. The diastema of a missing tooth is thus placed more distally in the dental arch to a position where aesthetics play a less important role.

In the studied cases, if there was insufficient bone for implantation, the interruption in the dental arch was either bridged by a fixed adhesive bridge or, if extra teeth were missing, it was replaced with a removable (cast cobalt-chromium) prosthesis.

Data collection

Baseline data were collected: sex, age at surgery, follow-up time, age at final X-OPT, type of bone graft, post-operative fistula with reoperation, pharyngoplasty, type of osteotomy (Le Fort I or bimaxillary osteotomy), number of surgeries, number of surgeries more than 6. The placement of tympanotomy tubes and rhinoplasties were not recorded for this study.

Scoring system

A Dento-Maxillary Scoring System was proposed to measure parameters that influence clinical outcome, specified at the level of the maxillary arch, hard palate and dentition. These parameters were considered critical in evaluation of the maxillary and dental treatment outcomes (see Table 2). The parameters used in the scoring system were: the (un)interrupted dental arch, sagittal frontal relationship (lateral cephalometric radiograph), the Bergland/Abyholm criteria and the presence of fistulas [9]. Sagittal relationship was scored as a negative overbite and overjet, an end-to-end relationship or a positive sagittal overbite and overjet. The ultimate goal was to create a practical and quick scoring system for patients with BCLP, which evaluated the end result of dento-maxillary treatment. As such, a score between one and ten was applied, comparable with the Visual Analogue Scoring System. The maximum score of the Dento-Maxillary Scoring System would be 10 (range from 1-10), with 1 being the worst outcome, and 10 the best.

Analysis of the dental arch, the sagittal relationship and the Bergland/Abyholm score was executed by two raters, KB and RE, and scores were discussed until consensus was reached [26]. The Bergland/Abyholm score is divided into four grades, with grade 1 being the best result and 4 the worst (see Table 2, Dento-Maxillary Scoring System and Figure 1, the reference pictures). The Bergland/Abyholm score was measured by use of panoramic x-rays, as recommended by Schultze-Mosgau et al. [27]. The Bergland/Abyholm score to be incorporated into the Dento-Maxillary Scoring System was measured for each side. The scores ranged from 0-1.5. As BCLP has two cleft sides, the maximum Bergland/Abyholm score was 3.

Table 2. Scoring of Dento-Maxillary treatment results

Parameter	Description	Score	Modality
1. Dental arch between both maxillary canines	Both sides with interruption with or without removable prosthetics	0	Panoramic radiographs
	One side interrupted	1	
	Two sides without interruption by use of implants or fixed prosthetics	2	
	Two sides uninterrupted without prosthetics	3	
2. Incisor relationship	Negative overbite and overjet	0	Lateral ceph
	End-to-end	1	
	Positive overbite and overjet	2	
3. Oronasal fistulas	Persisting fistula	0	Patient files
	Fistula closed after revision surgery	1	
	Fistula closed by SABG+PMO	2	
4. Bergland/ Abyholm criteria (per side*)	Grade 4 no bone	0	Panoramic radiographs
	Grade 3 Bone level less than $\frac{3}{4}$ of normal bone level	0.5	
	Grade 2 At least $\frac{3}{4}$ of normal bone level	1	
	Grade 1 Normal bone level	1.5	
Maximal total score	Dento-Maxillary BCLP Score	10	

*Bergland/Abyholm score per patient is measured on each cleft side separately.

Statistical analysis

The baseline characteristics of all patients were reported as categorical variables. The Statistical Package for the Social Sciences (SPSS for Mac, release 24.0.0.0, 2016, SPSS Inc.) was used for all statistical analyses. The independent T-test was used to calculate the effect of the preoperative parameters, an osteotomy, a pharyngoplasty, the presence of fistulas and number of surgeries on the outcome in the Dento-Maxillary Scoring System. The level of significance was set at $p < 0.05$.

RESULTS

Baseline data

Of 55 children with BCLP who were treated, the records of 45 were suitable for analysis. Ten patients were excluded in this study as the data needed for analysis were not available. All pertinent clinical baseline data for the 45 patients included in this study are presented in Table 3. The mean age at time of surgery was 12.0 years (8.9-16.4 yrs), and the mean follow-up time was 11.7 years (5.8-15.8 yrs). Panoramic and cephalometric radiographs were taken at a mean age of 19.5 years (15.04-28.9 yrs). Seven of the 45 patients underwent revisional surgery because of post-operative oronasal communications. Fourteen patients received a pharyngoplasty, because of velo-pharyngeal insufficiency. Twenty-three patients were treated with a (bi)maxillary osteotomy, because of either a retruded maxillary position or a malocclusion that could not be corrected by orthodontics alone.

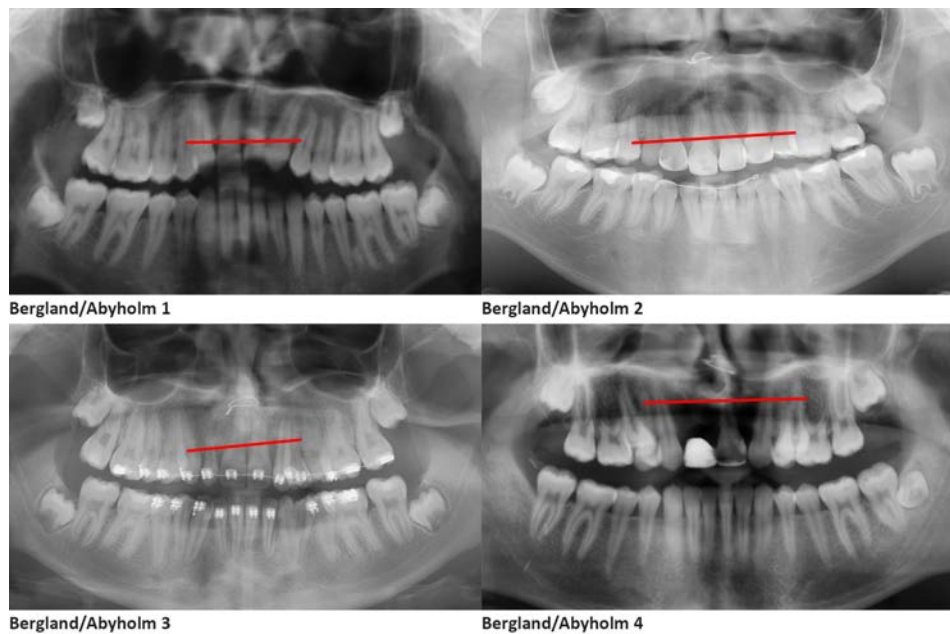


Figure 1. Bergland/Abyholm criteria, reference pictures

Table 3. Baseline clinical data

Number (n=45)		
Male	26	58%
Female	19	42%
Mean age at time of surgery	12 yr	range: 8.9-16.4 yr
Mean follow-up	11.7 yr	range: 5.8-15.8 yr
Mean age final X-panoramic taken	19.5 yr	range: 15.0-28.9 yr
Bonegraft mandibular symphysis	33	82.2%
Bonegraft crista illiaca	8	17.8%
Post-operative oronasal communications with reoperation (fistulas)	7	16%
Pharyngoplasty	14	31%
(bi)Maxillary osteotomy	23	51%
Average no. of surgical procedures	6	range: 3-10
Number of patients with >6 surgeries	15	33%

Table 4. Overview of patients who underwent extra surgical procedures under general anaesthesia, n=45

Patient number	Extra procedures above 6	Type of procedure
1	1	Redo closure soft palate
2	1	Redo closure lip
3	4	Redo closure lip, redo closure hard palate, redo SABG+PMO procedure, surgical removal of maxillary incisor
4	1	Redo closure lip
5	1	Redo SABG+PMO procedure
6	4	Redo closure soft palate, Redo closure lip, redo SABG+PMO procedure, removal of osteosynthesis material
7	2	Redo pharyngeoplasty, ligation of canine
8	2	Nose correction at early age, necrotectomy after nose correction
9	1	Tonsillectomy
10	2	Nose correction at early age, extraction of deciduous teeth
11	1	Redo SABG+PMO procedure
12	1	Gingiva correction
13	1	Pharyngeal fat graft
14	1	Additional fistula closure
15	2	Redo lip closure, additional lip correction

Number of surgeries

The average number of surgeries conducted under general anaesthesia was six (range: three-11). Additional surgeries are listed in Table 4.

Scoring system

The average Dento-Maxillary Score in this patient cohort was 7.6 (1-10, median: 8); see Table 5, which summarises all parameters separately. In the dental arch analyses, 31 patients had an uninterrupted dental arch. The average Bergland score was 2.07. In 30 patients, a final positive overbite and overjet incisor relationship was achieved. In 38 patients, the oronasal communication was closed after SABG+PMO. In 7 patients, the oronasal communication was closed through application of an additional procedure.

Table 6 shows the individual effect of separate parameters on the Dento-Maxillary Score. Only the parameter regarding fistulas showed a statistically significant effect on the total score, $p=0.001$.

Table 7 demonstrates the relationship between parameters of the Dento-Maxillary Scoring System. Both the presence of fistulas and the Bergland/Abyholm score proved to be of significant relevance to the presence of an uninterrupted dental arch, $p=0.002$ and $p=0.035$ respectively.

Table 5. Scores of factors that comprise Dento-Maxillary Scoring System, $n=45$

N=45	Score	
Mean Dento-Maxillary Score	7.6	SD 2.2
Dental arch analysis		
Both sides with interruption with or without removable denture	6	13%
One side interrupted	2	4%
Two sides without interruption (with implants or fixed prosthodontics)	6	13%
Two sides without interruption	31	69%
Bergland/Abyholm gradation (Number of sides = 90)		
Mean score (1.00-4.00)	2.07	SD 1.08
Score 1 or 2	63	76%
Score 3 or 4	27	24%
Incisor relationship		
Negative overbite and overjet	9	20%
End-to-end	6	13%
Positive overbite and overjet	30	67%
Oronasal fistulas around premaxilla		
Persisting fistula	0	0%
Fistula closed after revisional surgery	7	15.6%
Fistula closed after SABG+PMO	38	84.4%

Table 6. Effect of additional surgeries, pharyngoplasty, Le Fort I osteotomy and fistulas after the SABG+PMO and number of surgeries >6 on the end result of Dento-Maxillary Scoring System, n=45

	n	Mean Score	Range of Score	SD	P value
All patients	45	7.6	(1-10)	2.20	
Pharyngoplasty	14	8.178	3-10	1.97	0.256
Le Fort I	23	7.304	1-10	2.61	0.324
Number of surgeries > 6	15	7.933	2-10	2.25	0.448
Fistulas	7	5.286	1-9	2.86	0.001

Calculated using the independent sample T-test

Table 7. Effect of fistulas on different parameters of the Dento-Maxillary Scoring System, n=45

	Mean	SD	P value
Fistulas vs. Bergland/Abyholm	1.5714	1.304	P=0.275
Fistulas vs. dental arch	1.2857	1.380	P=0.002
Fistulas vs. incisor relationship	1.4286	0.975	P=0.895
Bergland/Abyholm vs. dental arch	1.500	1.109	P=0.037

Calculated using the independent sample T-test p < 0.05

DISCUSSION

The present study analyses the final results of alveolar cleft closure, orthodontics and prosthodontic rehabilitation of 45 patients with BCLP who were treated in a dedicated cleft-care centre. The result is presented through application of a new proposed Dento-Maxillary Scoring System. A previous study has addressed dental arch morphology and skeletal relationship [17]. This new scoring system is intended to cover the complete dento-maxillary result of BCLP treatment. It applies four typical factors to measure dental maxillary outcome. To analyse the result at bone level, the criteria developed by Bergland/Abyholm have been used and extended through consideration of the presence or absence of postoperative fistulas, as applied by others [9, 27]. Dental factors play an important role in BCLP stigmata [28]. Therefore, the complete or incomplete nature of the dental arch and the sagittal relationship of the incisors are included as factors in this scoring system.

Surgical protocol

The protocol used in our study is secondary alveolar bone grafting (SABG) combined with a premaxilla osteotomy. The eruption of the canine is used as a guidance for planning of the surgery. In the literature different protocols are used, secondary alveolar bone grafting without osteotomy of the premaxilla, or early secondary alveolar bone grafting, with use of the incisors as a guidance for planning [29]. For an optimal timing of alveolar bone grafting,

not only the residual bone is important but also the residual growth and eventually growth retardation if surgery is done at an early age [30]. More recent research shows promising results of an early alveolar bone grafting procedure, but needs more investigation of the skeletal growth [31].

In the present study a premaxilla osteotomy was done in all cases, in order to gain access to the nasal floor and ensure watertight closure of the nasal mucosa. In the presented patient group, access to the nasal floor was difficult due to the almost complete closure of the hard palate in earlier surgeries. A review addressing the different protocols for closure of the alveolar cleft and the effect on outcome was done by [32]. 51.1% of the patients in the present cohort were treated with a (bi)maxillary osteotomy to correct their skeletal profile. Bartzela et al. presented a study comparing different surgery protocols between cleft centers, including centers executing a premaxilla osteotomy. They did not find significant differences in growth between centers using the BAURU-yardstick [33]. However, it still might be possible that midfacial growth is affected by the osteotomy of the premaxilla. The effect of other and earlier fulfilled surgical procedures should also not be ruled out. Recently, standardisation of the evaluation of cleft lip and palate care using patient-reported outcome measures (PROMs) has been advocated. Also, the International Consortium for Health Outcomes Measurement (ICHOM) has started to develop a set of questionnaires and guidelines for cleft lip and palate care. The parameters that are recommended to be scored are: mastication, oral health, dental health and occlusion [34]. Mastication and oral health are scored by questionnaires. A Decay-Missing-Filled index (DMF) is applied for dental health, and the Goslon Yardstick for occlusion [22, 33]. These scoring systems are designed to enable inter-centre evaluation of all aspects of BCLP treatment. The patient-reported outcomes of this BCLP cohort had already been evaluated in an earlier study by Kappen et al. [35]. However, the proposed Dento-Maxillary Scoring System is useful to provide a quick, overall clinical evaluation of dental, orthodontic and prosthetic end results after BCLP treatment. It focusses on clinical outcome, not patient-reported outcome.

In literature, several other scoring systems that concern the outcomes of cleft lip and palate treatments are described. These scoring systems are designed to score maxillary growth and do not include the different dental aspects of cleft lip and palate treatment, i.e. surgery, orthodontics and prosthetics. For instance, the BAURU-yardstick and the Huddart and Bodenham index were developed to analyse growth at the level of occlusion [18, 21, 36].

Validation and alveolar bone height

In our proposed scoring system, the validated Bergland/Abyholm criteria were used to analyse bone height. In 34 patients, the Bergland/Abyholm score was 1 or 2, which seemed to be a sufficient result that was comparable with those reported in the literature [27]. The three other factors that were added (dental arch, sagittal maxillary relation and fistula) were objective parameters that did not require validation. This new method scored the complete treatment period throughout childhood until the age of at least 18 years on a scale from 0 to 10. This BCLP cohort scored an average of 7.62 in this new scoring system. It would be of interest to compare this score with those of other cleft care units.

Fistulas

It was observed that the presence of residual fistulas that had to be closed through application of additional surgery was associated with a lower score in the Dento-Maxillary Scoring System. The present study shows a significant correlation between the presence of residual fistulas after closure of the alveolar cleft and the end result of the dental arch at the end of follow up ($p=0.002$). Clinically relevant residual fistulas occur immediately around the premaxillary bone and impair alveolar ridge integrity. This explains the significant relation between the interrupted dental arch and the occurrence of fistulas. To the best of our knowledge, this correlation between the occurrence of fistulas and that of an interrupted dental arch has not been described previously.

In this study, fistulas were found to occur after SABG+PMO in 7 patients. The presence of fistulas after the SABG+PMO procedure may be related to difficulties with closure of the several layers during surgery. It has been reported that nasal closure can be obtained more accurately if SABG is combined with a PMO [37]. Scott described the consecutive completed treatment of 44 patients with BCLP through SABG+PMO. They found residual fistulas in 11% of the patients, having a slightly less percentage of fistulas after surgery [38].

Pepper et al. studied the presence of fistulas in uni- and bilateral cleft cases. They reported an overall fistula rate of 10% post SABG, and an 8% rate in the bilateral cases. They also performed PMOs in all cases, as in our cohort. However, information on the pre- and post-operative positions of the premaxillae is missing in the report of this study. The mean age at which surgery was done in the present study was 12.0 years, whereas in the Pepper et al. study the mean age was 11.4 years [39]. As timing is important in relation to outcome due to the eruption of the canine in the cleft, the higher percentage of fistulas in our study might be explained by the average age of 12.0 years. It should be mentioned that in the present study as well as in the study of Pepper et al. the range of the age of inclusion is wide, which could make the groups less comparable.

Orthodontics

In the present study, orthodontic treatment achieved uninterrupted dental arches on both sides in 69% of the cases. In a study on timing of alveolar bone-grafting surgery in unilateral cleft patients, Enemark et al. reported successful outcomes without prosthodontics in 39% of the patients only [40]. Over the years, protocols have been modernised and this has resulted in a better overall outcome for the patient.

In literature it is shown that the orthodontics protocol is an important factor in achieving a good end result. Pre-surgical as well as post-surgical orthodontics are important in achieving the best end result. Yu-Fang Liao et al. did find in their study better results with presurgical repositioning of the adjacent teeth and post surgical movement of the teeth into the grafted area [41].

Prosthodontics

In cases of missing lateral incisors, our treatment protocol advocated that the distal teeth should be mesialised into the grafted area. If indicated, prosthodontic rehabilitation with

an implant was then executed in the premolar region. This procedure has been found to be more reliable than implantation in the alveolar cleft area [42]. Härtel et al. suggested that the use of implants in the grafted area can be reliable [43]. However, implants should be placed shortly after secondary alveolar bone grafting; at the Utrecht cleft team this is not considered an option in children before the end of adulthood. By the strategy of mesialisation of the posterior teeth, as advocated by Semb and Ramstad, natural teeth are retained in the aesthetic zone, and stable prosthodontics are positioned in the lateral part of the maxilla, outside the cleft area. In the Dento-Maxillary Scoring System, this outcome would be scored as an uninterrupted arch [44]. A second option would be to preserve the diastema and place an implant in the grafted area [45, 46]. However, if fistulas occurred after SABG and PMO treatment, the amount of bone present in the cleft might be reduced, which would lead to difficulty during placement of implants in the grafted area or orthodontic mesialisation of the distal teeth. As a result, these patients would be more likely to be fitted with removable prosthodontics, and this result would give lower overall scores in the Dento-Maxillary Scoring System. This outcome is demonstrated in Table 7 by the association between a lower Bergland/Abyholm score and an interrupted dental arch.

5

Multiple surgeries

Patients with BCLP need to undergo multiple surgeries to reach an acceptable end result. It is generally seen in the patient group with clefts that they develop an aversion to surgery over time. Therefore, from a patient's point of view it is important to reach an acceptable end result with as few surgeries as possible. The average number of surgeries under general anaesthesia at the end of follow-up was six (range 3-11). That seems reasonable, since patients with BCLP often need six operations to achieve a satisfactory end result in which a positive vertical overbite and sagittal overbite, an uninterrupted arch, and no fistulas are found: four separate primary closures of lip, soft palate, hard palate and alveolar cleft and in addition a pharyngoplasty, and a maxillary osteotomy may be necessary. Late secondary nose- and/or lip-corrections were not taken into consideration in this study, as these procedures were performed after final orthodontic treatment and orthognathic surgery, usually in late teenage years or early adulthood. Cohen et al. reported that the average number of surgeries in patients with BCLP was eight. However, in 62% of their patients, a primary lip adhesion was carried out, and they included secondary nose corrections in their data. If these figures were excluded, their result would be comparable with that found for the Utrecht cohort (Cohen et al., 1995). In the Utrecht centre, a lip adhesion is rarely part of the BCLP treatment protocol; but doing a lip adhesion results in at least one additional surgical treatment.

In the present study a pharyngoplasty was done in 14 patients (31%). The protocol used for closure of the hard palate is comparable to the protocol used at the same centre for patients with an unilateral cleft lip and palate. A study was done to investigate this group of patients and a pharyngoplasty rate of 40% was found [47]. This group was compared with a patient group in a study by Lohmander et al. reporting a pharyngoplasty rate of 11%,

which is remarkably lower [48]. It might be possible that these patients benefit from an early closure of the hard palate. However, the study by Kappen et al. demonstrated a very heterogenic outcome between the different protocols [47].

Pai et al. reduced the number of surgical procedures for patients with unilateral cleft lip and palate by combining speech-enhancing surgery with the SABG procedure. This reduced the total number of procedures to an average of 4.8; the researchers did not mention the range in their report [18]. Moreover, a pharyngoplasty and the closure of the alveolar cleft may be carried out at different times.

Strengths and limitations

Some limitations are present in this study, which may have some implications for the outcome of the research. In the present study, sample size and power were not calculated. All patients at the Utrecht centre with BCLP who were available in the selected time period were selected and included. The data of these patients were retrieved retrospectively by means of analysis of the patient files. In this patient group, there is a wide range in the age at surgery, follow-up time, and age at which the x-rays were taken. This is due to the fact that data were collected during regular consultations. This may influence the results of this study.

It is known that if secondary alveolar bonegrafting is done at an older age, the results of the procedure may be worse. The wide range in the last follow-up radiographs may be of limited effect, as all radiographs were taken at the end of the treatment protocol.

This study demonstrates the end result of a large cohort of BCLP patients with a long follow-up period.

CONCLUSION

The proposed Dento-Maxillary Scoring System (DMSS) is a straightforward and easy-to-use tool to describe and analyse overall dento-maxillary reconstruction at the end of treatment for patients with BCLP. An average of 7.6 on a scale from 1 to 10 was scored in the BCLP group tested. This study shows that the persistence of oronasal fistulas in patients with BCLP, has a relevant impact on the interruption of the dental arch and influences the dental result at the end of the second decade.

List of abbreviations

BCLP: Bilateral cleft lip and palate

SABG: Secondary alveolar bone grafting

PMO: Premaxilla osteotomy

SABG +PMO: Secondary alveolar bone grafting and premaxilla osteotomy

Yrs: Years

WCH cleft team Utrecht: Wilhelmina Children's Hospital cleft team at the University Medical Center Utrecht, the Netherlands

REFERENCES

- [1] Bittermann GKP, de Ruiter AP, Janssen NG, et al. Management of the premaxilla in the treatment of bilateral cleft of lip and palate: what can the literature tell us? *Clinical Oral Investigations* 2016; 20: 207–217.
- [2] Vellone V, Cirignaco G, Cavarretta B, et al. Canine Eruption after Secondary Alveolar Bone Graft in Unilateral Cleft Lip and Palate Patients. *Journal of Craniofacial Surgery*; 28. Epub ahead of print 2017. DOI: 10.1097/SCS.0000000000003659.
- [3] Stoelinga PJW, Haers PEJJ, Leenen RJ, et al. Late management of secondarily grafted clefts. *International Journal of Oral and Maxillofacial Surgery* 1990; 19: 97–102.
- [4] Bittermann GKP, Es RJJ van, Ruiter AP de, et al. Retrospective analysis of clinical outcomes in bilateral cleft lip and palate patients after secondary alveolar bone grafting and premaxilla osteotomy, using a new dento-maxillary scoring system. *Journal of Cranio-Maxillofacial Surgery*. Epub ahead of print 2020. DOI: 10.1016/j.jcms.2020.12.006.
- [5] Rawashdeh MA, Telfah H. Secondary alveolar bone grafting: the dilemma of donor site selection and morbidity. *The British journal of oral & maxillofacial surgery* 2008; 46: 665–670.
- [6] Åbyholm FE, Bergland O, Semb G. Secondary bone grafting of alveolar clefts: A surgical/orthodontic treatment enabling a non-prosthetic rehabilitation in cleft lip and palate patients. *Scandinavian Journal of Plastic and Reconstructive Surgery and Hand Surgery* 1981; 15: 127–140.
- [7] Jia YL, Fu MK, Ma L. Long-term outcome of secondary alveolar bone grafting in patients with various types of cleft. *British Journal of Oral and Maxillofacial Surgery* 2006; 44: 308–312.
- [8] Janssen NG, Schreurs R, Bittermann GKP, et al. A novel semi-automatic segmentation protocol for volumetric assessment of alveolar cleft grafting procedures. *Journal of Cranio-Maxillofacial Surgery* 2017; 45: 685–689.
- [9] Bergland O, Semb G, Abyholm FE. Elimination of the residual alveolar cleft by secondary bone grafting and subsequent orthodontic treatment. *The Cleft palate journal* 1986; 23: 175–205.
- [10] Andlin-Sobocki A, Eliasson LÅ, Paulin G. Periodontal evaluation of teeth in bone grafted regions in patients with unilateral cleft lip and cleft palate. *American Journal of Orthodontics and Dentofacial Orthopedics* 1995; 107: 144–152.
- [11] Bittermann GKP, van Es RJJ, de Ruiter AP, et al. Incidence of complications in secondary alveolar bone grafting of bilateral clefts with premaxillary osteotomy: a retrospective cohort study. *Clinical Oral Investigations* 2020; 24: 915–925.
- [12] Tanimoto K, Yanagida T, Tanne K. Orthodontic treatment with tooth transplantation for patients with cleft lip and palate. *Cleft Palate-Craniofacial Journal* 2010; 47: 499–506.
- [13] Zachrisson BU. Letters to the editor. *American Journal of Orthodontics and Dentofacial Orthopedics* 2004; 126: A13–A15.
- [14] Robertsson S, Mohlin B. The congenitally missing upper lateral incisor. A retrospective study of orthodontic space closure versus restorative treatment. *European journal of orthodontics* 2000; 22: 697–710.
- [15] Voshol IE, van der Wal KGH, van Adrichem LNA, et al. The frequency of Le Fort I osteotomy in cleft patients. *Cleft Palate-Craniofacial Journal* 2012; 49: 160–166.
- [16] Good PM, Mulliken JB, Padwa BL. Frequency of Le Fort I osteotomy after repaired cleft lip and palate or cleft palate. *The Cleft palate-craniofacial journal : official publication of the American Cleft Palate-Craniofacial Association* 2007; 44: 396–401.

- [17] Bittermann GKP, de Ruiter AP, Bittermann AJ, et al. Midfacial growth and dental arch relationships in bilateral cleft palate following secondary alveolar bone grafting and orthodontic intervention: Factors predicting a Le Fort I osteotomy at age 18. *Journal of Cranio-Maxillofacial Surgery* 2018; 46: 1764–1771.
- [18] Pai BCJ, Hung YT, Wang RSH, et al. Outcome of Patients with Complete Unilateral Cleft Lip and Palate: 20-Year Follow-Up of a Treatment Protocol. *Plastic and Reconstructive Surgery* 2019; 143: 359e–367e.
- [19] Mosmuller DGM, Don Griot JPW, Bijnen CL, et al. Scoring systems of cleft-related facial deformities: A review of literature. *Cleft Palate-Craniofacial Journal* 2013; 50: 286–296.
- [20] Mulder FJ, Mosmuller DGM, De Vet HCW, et al. The cleft aesthetic rating scale for 18-year-old unilateral cleft lip and palate patients: A tool for nasolabial aesthetics assessment. *Cleft Palate-Craniofacial Journal* 2018; 55: 1006–1012.
- [21] Ozawa TO, Shaw WC, Katsaros C, et al. A new yardstick for rating dental arch relationship in patients with complete bilateral cleft lip and palate. *The Cleft palate-craniofacial journal : official publication of the American Cleft Palate-Craniofacial Association* 2011; 48: 167–172.
- [22] Anaise JZ. Measurement of dental caries experience-modification of the DMFT index. *Community Dentistry and Oral Epidemiology* 1984; 12: 43–46.
- [23] MILLARD DR. Columella lengthening by a forked flap. *Plastic and reconstructive surgery and the transplantation bulletin* 1958; 22: 454–7.
- [24] Sommerlad BC. A technique for cleft palate repair. *Plastic and Reconstructive Surgery* 2003; 112: 1542–8.
- [25] von Langenbeck B. Operation der angeboren totalen Spaltung des harten Gaumens nach einer neuen Methode. *Drsch Klin* 1861; 8: 231.
- [26] Bergland O, Semb G, Abyholm FE. Elimination of the residual alveolar cleft by secondary bone grafting and subsequent orthodontic treatment. *The Cleft palate journal* 1986; 23: 175–205.
- [27] Schultze-Mosgau S, Nkenke E, Schlegel AK, et al. Analysis of bone resorption after secondary alveolar cleft bone grafts before and after canine eruption in connection with orthodontic gap closure or prosthodontic treatment. *Journal of oral and maxillofacial surgery : official journal of the American Association of Oral and Maxillofacial Surgeons* 2003; 61: 1245–1248.
- [28] Posnick JC, Kinard BE. *Challenges in the successful reconstruction of cleft lip and palate: Managing the nasomaxillary deformity in adolescence*. 2020. Epub ahead of print 2020. DOI: 10.1097/PRS.0000000000006614.
- [29] Fahradyan A, Tsuha M, Wolfswinkel EM, et al. Optimal Timing of Secondary Alveolar Bone Grafting: A Literature Review. *Journal of Oral and Maxillofacial Surgery* 2019; 77: 843–849.
- [30] Padwa BL, Sonis A, Bagheri S, et al. Children with repaired bilateral cleft lip/palate: Effect of age at premaxillary osteotomy on facial growth. *Plastic and Reconstructive Surgery* 1999; 104: 1261–1269.
- [31] Siegenthaler M, Bettelini L, Brudnicki A, et al. Early versus late alveolar bone grafting in unilateral cleft lip and palate: Dental arch relationships in pre-adolescent patients. *Journal of Cranio-Maxillofacial Surgery* 2018; 46: 2052–2057.
- [32] Bittermann GKP, de Ruiter AP, Janssen NG, et al. Management of the premaxilla in the treatment of bilateral cleft of lip and palate: what can the literature tell us? *Clinical Oral Investigations*. Epub ahead of print 2015. DOI: 10.1007/s00784-015-1589-y.
- [33] Bartzela T, Katsaros C, Shaw WC, et al. A longitudinal three-center study of dental arch relationship in patients with bilateral cleft lip and palate. *The Cleft palate-craniofacial journal : official publication of the American Cleft Palate-Craniofacial Association* 2010; 47: 167–174.

- [34] Allori AC, Kelley T, Meara JG, et al. A Standard Set of Outcome Measures for the Comprehensive Appraisal of Cleft Care. *The Cleft Palate-Craniofacial Journal* 2017; 54: 540–554.
- [35] Kappen IFPM, Bittermann GKP, Stock NM, et al. Quality of Life and Patient Satisfaction in Adults Treated for a Cleft Lip and Palate: A Qualitative Analysis. *Cleft Palate-Craniofacial Journal* 2019; 56: 1171–1180.
- [36] Huddart AG, Bodenham RS. The evaluation of arch form and occlusion in unilateral cleft palate subjects. *The Cleft palate journal* 1972; 9: 194–209.
- [37] Scott R, Scott J, Stagnell S, et al. Outcomes of 44 Consecutive Complete Bilateral Cleft Lip and Palate Patients Treated with Secondary Alveolar Bone Grafting and Premaxillary Osteotomy. *The Cleft Palate-Craniofacial Journal* 2017; 54: 249–255.
- [38] Scott R, Scott J, Stagnell S, et al. Outcomes of 44 consecutive complete bilateral cleft lip and palate patients treated with secondary alveolar bone grafting and premaxillary osteotomy. *Cleft Palate-Craniofacial Journal* 2017; 54: 249–255.
- [39] Pepper HB, Revington PJ, Deacon S, et al. Impact of secondary alveolar bone grafting on the symptoms of reflux in oronasal fistulas: A patient-related outcome study. *Cleft Palate-Craniofacial Journal* 2014; 51: 270–273.
- [40] Enemark H, Krantz-Simonsen E, Schramm JE. Secondary bonegrafting in unilateral cleft lip palate patients: indications and treatment procedure. *International Journal of Oral Surgery* 1985; 14: 2–10.
- [41] Liao YF, Huang CS. Presurgical and postsurgical orthodontics are associated with superior secondary alveolar bone grafting outcomes. *Journal of Cranio-Maxillofacial Surgery* 2015; 43: 717–723.
- [42] Cune MS, Meijer GJ, Koole R. Anterior tooth replacement with implants in grafted alveolar cleft sites: A case series. *Clinical Oral Implants Research* 2004; 15: 616–624.
- [43] Härtel J, Pögl C, Henkel KO, et al. Dental implants in alveolar cleft patients: A retrospective study. *Journal of Cranio-Maxillofacial Surgery* 1999; 27: 354–357.
- [44] Semb G, Ramstad T. The influence of alveolar bone grafting on the orthodontic and prosthodontic treatment of patients with cleft lip and palate. *Dental update* 1999; 26: 60–64.
- [45] Cassolato SF, Ross B, Daskalogiannakis J, et al. Treatment of dental anomalies in children with complete unilateral cleft lip and palate at sickKids hospital, Toronto. *Cleft Palate-Craniofacial Journal* 2009; 46: 166–172.
- [46] Alberga JM, Stellingsma K, Meijer HJA, et al. Dental implant placement in alveolar cleft patients: a retrospective comparative study on clinical and aesthetic outcomes. *International Journal of Oral and Maxillofacial Surgery* 2020; 49: 952–959.
- [47] Kappen IFPM, Bittermann D, Janssen L, et al. Long-term follow-up study of young adults treated for unilateral complete cleft lip, alveolus, and palate by a treatment protocol including two-stage palatoplasty: Speech outcomes. *Archives of Plastic Surgery* 2017; 44: 194–209.
- [48] Lohmander A, Friede H, Lilja J. Long-term, longitudinal follow-up of individuals with unilateral cleft lip and palate after the gothenburg primary early veloplasty and delayed hard palate closure protocol: Speech outcome. *Cleft Palate-Craniofacial Journal* 2012; 49: 657–671.



CHAPTER 6

Taking the endochondral route to craniomaxillofacial bone regeneration: a logical approach?

Published at Journal of Cranio-Maxillofacial Surgery 2017
DOI: 10.1016/j.jcms.2017.03.025

Elmer C Kruijt Spanjer, Gerhard KP Bittermann, Inge EM van Hooijdonk,
Antoine JWP Rosenberg, Debby Gawlitta

INTRODUCTION

The complex anatomy of the skull and face poses a challenge to surgeons confronted with the reconstruction of critical size defects of the cranial or facial skeleton. Critical size defects in bone are defined as orthotopic defects that will not heal without intervention. These may be a result of trauma, oncological resection or congenital malformation [1, 2, 3, 4]. With an annual incidence of up to 6.9 per 100,000 people for oral cancer, and 1 per 700 live births for cleft lip and palate, surgeons worldwide are confronted with such defects on a weekly basis [4, 5, 6]. Due to the potentially severe impact of a craniofacial critical size defect on a patient's functional, esthetic and psychological development and quality of life, proper reconstruction is essential.

The complexity and size of craniofacial reconstructions that surgeons are facing have led to a need to explore different reconstructive techniques. The current gold standard of treatment for critical size calvarial and facial bone defects is autologous bone grafting using either free or vascularized bone grafts from the calvarium, chin, rib, scapula, iliac crest, or fibula. [7, 8]. Nevertheless, complications frequently arise when transplanting autologous bone. Complications associated with iliac crest bone harvest have been reported up to 19% and include chronic pain, skin sensitivity disorders, and complicated wound healing. This can lead to hypertrophic scarring or infection, fracture, and prolonged length of hospitalization – all associated with additional morbidity and medical cost [9, 10]. Furthermore, the most frequently reported complications caused by fibular bone harvesting are postoperative limited mobility of the ankle joint, pain, and swelling; occurring in 50% of patients [11, 12]. Besides donor site morbidity and surgical complications, reconstruction by autologous bone grafting can lead to prolonged operation time due to the need for microvascular anastomosis of the transplant, complex harvesting techniques at a second surgical site, and double surgical teams. An extended operation time correlates with a heavier burden on the patient, often resulting in longer time of admittance [13]. The major long term complication associated with autologous bone grafting is failure of the graft itself. Failure rates of up to 43% have been reported for autologous iliac crest bone grafts for the mandible[14]. This failure is typically due to limited remodeling and poor osseointegration of the graft [15].

The ideal bone substitute has osteoinductive and osteoconductive properties without excessive triggering of the host immune system. Autologous bone grafting possesses these qualities, but has the aforementioned disadvantages. Alternatively, allograft bone transplants have a rather unlimited availability but they are less osteoinductive and can trigger a host response or transmit disease [16]. These limitations have prompted an increased demand for alternatives. New solutions are emerging in the form of bone tissue engineering, or the growing of new autologous bone from stem cell cultures. This approach holds the promise of the ability to create new, optimally molded and organized autologous bone tissues without the need to damage a donor site elsewhere in the body [17].

Tissue engineering involves a combination of three core components: cells, scaffolds, and signals [18]. Typically, multipotent mesenchymal stromal cells (MSCs) are harvested from the patient's bone marrow

and ex vivo stimulated with signals to differentiate towards the osteogenic lineage, frequently with the use of biomaterial-based scaffolds [18, 19, 20]. However, translating this approach, mimicking intramembranous bone formation with MSCs, from the laboratory to the clinic has met with limited success. Consequently, attention has shifted towards investigation of bone regeneration based on the alternative endochondral route to bone formation [21, 22]. Endochondral ossification involves replacement of cartilage by bone, a temporal process that is spatially illustrated by the various zones in the growth plates. This route begins with a chondrogenic template that can be engineered, again, using MSCs. Following MSC condensation, they can differentiate into the chondrogenic lineage. The transition of these chondrocytes into a hypertrophic state is critical, leading to the mineralization of the deposited cartilage matrix. A multitude of growth factors is released that orchestrates subsequent conversion of this template into bone tissue.

Until now, the endochondral route has not been considered for craniofacial bone regeneration, because most bone in the craniofacial region is formed by intramembranous bone formation.

Therefore, this review discusses the sense and non-sense of exploring this novel reconstructive option for craniofacial bone defects. First, the natural mechanisms of bone formation and healing in the cranial and facial region will be recapitulated. Then, pioneer work on endochondral bone regeneration with cartilage transplants from the previous century will be highlighted. Thirdly, recent advances in endochondral bone regeneration based on MSCs and on alternative cell sources are described. Finally, clinical experience with endochondral bone formation will be discussed before these aspects are combined to provide a prospective glance of future applications.

Embryology of the human face, teeth and craniofacial skeleton

The embryologic foundation of the facial skeleton starts after 8 days of gestation. At this stage, the human embryoblast takes on the form of a two-layered disk, containing two germ layers called the ectoderm and endoderm. This formation is completed after 2 weeks of development. In the third week a third germ layer, the mesoderm is added [23]. A fourth germ layer is formed later through folding of the ectoderm, leading to the formation of the neural groove and the neural tube. As the neural tube forms, an area is identified as the neural crest. Cells from this neural crest eventually migrate away from the neural tube to the developing facial region. These cells are known as the neural crest cells (NCCs). The neural crest and its migrating NCCs comprise the fourth germ layer, which is crucial in the development of the head [23, 24]. A lot of work has been focused on the exact formation and fate of these neural crest cells [25].

After the folding of the ectoderm and the formation of the neural crest cells, 4 germ layers are recognized that can be subdivided into the 5 embryologic layers that shape the human face. Each layer is responsible for the formation of different tissues, which can be found in Table 1 [23]. Most of the connective tissues of the head are derived from the NCCs and are referred to as ecto-mesenchyme or mesectoderm, whereas connective tissues in the rest of the body originate from mesoderm and are referred to as mesenchyme [23, 25].

Table 1. Fate of the five embryologic germ layers

Germ layer	Derivatives
epidermal-Ectoderm	Epidermis, hair, cutaneous glands, anterior pituitary gland, parenchyma of salivary glands, enamel of teeth, lens, and inner ear.
neural-Ectoderm	Posterior pituitary gland, pineal body, retina, central nervous system.
Neural crest cells	Cranial and sensory ganglia and nerves, ectomesenchymal bones and skull, dentin, dental pulp, periodontal ligament, alveolar bone, connective tissue of the head.
Mesoderm	Connective tissue, dermis.
Endoderm	Epithelial component of pharynx, tonsil, tympanic cavity, etc.

Fate of the 5 embryologic germ layers. (*Nanci*, 2013)

Subsequently the human embryo develops the branchial arches, which are infiltrated by NCCs to form a cartilage tube, known as the arch cartilage. The arch cartilage of the first branchial arch has a close relationship with the developing mandible, which is formed through an interaction between epithelium and ecto-mesenchyme. This interaction leads to the condensation of neural crest cells, forming an osteoid bone matrix that is subsequently mineralized. This process is known as direct bone formation, or intramembranous ossification. The maxilla is also formed by intramembranous ossification through the fusion of frontal, nasal and maxillary growth centers. The facial bones and cranial vault (but not the base of the skull) are also formed through intramembranous ossification [23].

Besides intramembranous ossification, endochondral bone formation takes place in the craniomaxillofacial region. In the craniomaxillofacial bones, endochondral bone formation has been described for the growing mandibular collum, base of the skull, occipital bones, and the temporal bones [23, 26]. This process can further take place in the natural healing of fractures in craniomaxillofacial bone structures, as discussed hereafter [27].

In endochondral ossification, the initial stage is the condensation of mesenchymal cells. These differentiate into chondrocytes that form a cartilage anlage [28]. Hypertrophy of the chondrocytes leads to secretion of alkaline phosphatase (ALP) and angiogenic signals, causing calcification of the cartilage matrix and vascular invasion, respectively. Further, hypertrophy of the chondrocytes increases the metabolic demands, which can no longer be sustained within this calcified matrix, leading to chondrocyte death (or transdifferentiation) and cavities within the mineralized cartilage matrix [29, 30]. Osteoprogenitor cells enter these cavities and use the calcified matrix as a scaffold as they secrete osteoid, forming the unmineralized base of trabecular and cortical bone extracellular matrices [28].

The formation of the teeth and their supportive tissues starts on day 37 of gestation, as ectodermal epithelium starts to thicken on the developing mandible and maxilla. The thickened epithelium grows into the underlying ecto-mesenchyme, where these ectodermal outgrowths are surrounded by condensing neural crest cells. The infiltrating ectodermal cells form the enamel organ, responsible for the formation of ameloblasts and the enamel

cap. The condensed neural crest cells create the dental papilla which will create the dentin and pulp. The neural crest cells also form a layer, encapsulating the developing tooth bud, which will later form the dental follicle – eventually giving rise to the tissues supporting the tooth [23].

In summary, ectomesenchyme – or rather the neural crest cells – plays an important role in the formation of the human face. After migration, they differentiate into precursors of chondroblasts, fibroblasts, osteoblasts, odontoblasts, and many more, giving rise to the facial skeleton, its muscles, teeth and (ecto)mesenchymal structures [31]. The craniomaxillofacial skeleton is developed through both intramembranous and endochondral ossification. (see Figure 1)

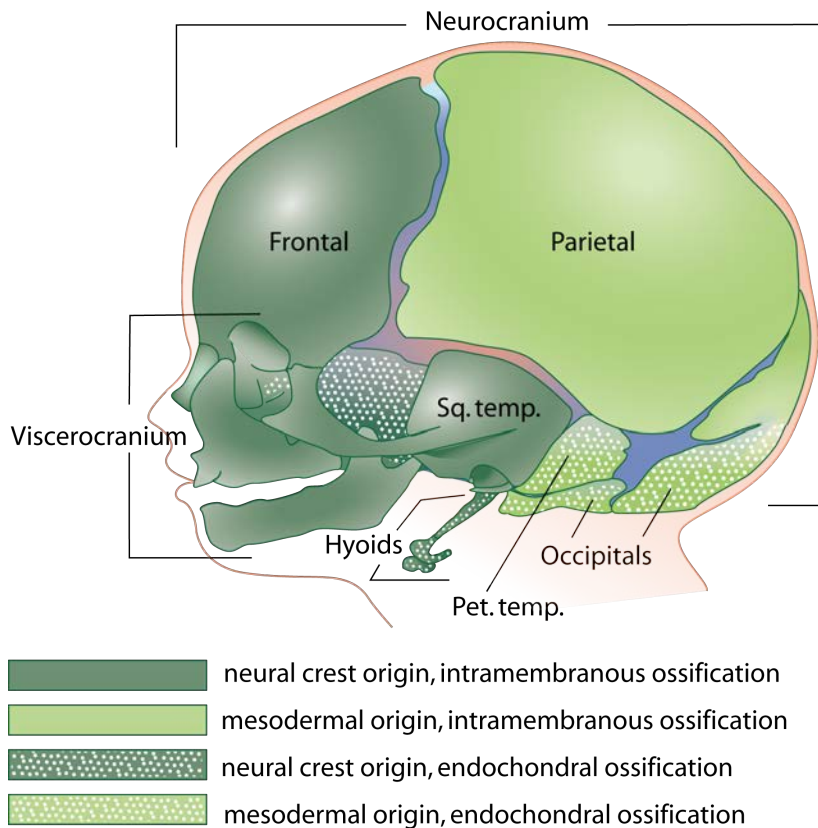


Figure 1. Formation of the craniofacial skeletal structures in the developing head. Regions are distinguished based on neural crest or mesodermal origin, as well as the embry- ological mechanism of bone formation (Adapted from T.W. Sadler 2015: Langman's Medical Embryology 13th edition).

Healing of bone

Damage to bone after surgery or trauma can be repaired via several mechanisms, dependent on the biophysical environment. The environment is dependent upon the degree of immobilization, the extent of trauma, and ongoing biological processes. This governs the endochondral and/or intramembranous bone formation processes that will take place to regenerate the fractured bone. In general, bone tissue has a high innate regenerative potential but around 10% of fractures fail to heal [32]. In bone healing, two patterns can be discerned. First, direct contact repair or *primary bone repair* is mediated by intraosseous osteoblasts and osteoclasts. In this mechanism, necrotic bone is resorbed by osteoclasts on either side of the bony defect after which osteoblasts synthesize lamellar bone that requires no remodeling of the repaired bone. Primary bone repair occurs in fracture sites with rigid stability and interfragmentary spaces of <0.1mm. These defects can be found after low impact trauma, or after open reduction and internal fixation of displaced fractures such as a fractures of the body of the mandible [33]. Second, callus formation repair or *secondary repair* is usually mediated by the inner periosteal layer and/or marrow tissues. This process of healing highly resembles the developmental endochondral bone formation, and includes an inflammatory stage, followed by the formation of a soft callus that subsequently mineralizes and remodels into bone. Callus formation is seen during the healing of displaced fractures without surgical intervention, and treated by immobilization with mandibulomaxillary fixation [27, 33, 34].

Even though most bones in the facial skeleton are formed through intramembranous ossification, after a fracture mandibular cells have shown to be able to form bone through endochondral ossification in non-stabilized fractures [27]. Thus, the use of endochondral bone formation for craniofacial bone tissue engineering would mimic a natural way of bone healing in the facial skeleton.

A historical perspective on endochondral bone regeneration

Relying on a direct pathway, tissue engineers have focused their attention mainly on application of intramembranous ossification [19, 35, 36]. The most commonly used source of adult stem cells for research in bone regeneration resides in the bone marrow, the MSCs [6, 18, 37]. By definition, these adult multipotent cells retain the potential to differentiate into a variety of mesenchymal cell types including chondrogenic, osteogenic, adipogenic, and myogenic lineages [18, 38]. MSC-like cells have to date been isolated from various tissues such as skin, muscle, and adipose tissue. Using MSCs, tissue engineers managed to form small bone-like constructs. Several studies have been reported describing the formation of extracellular bone matrix components *in vitro*, however, the translation to *in vivo* bone formation has thus far proved difficult [38, 39, 40]. The major challenge to be overcome is the scale-up of construct size (mm-scale) to dimensions of clinical relevance (cm-scale). The limiting factor here is the lack of vasculature and/or nutrients, oxygen, and waste transport, as osteoblasts and osteocytes are highly dependent on these for their survival [41]. Due to this shortcoming, stem cell-based bone constructs exceeding the millimeter scale have

consistently undergone necrosis in their cores, either while in culture or shortly after *in vivo* implantation [42]. In contrast to osteoblasts, chondrocytes can thrive under low oxygen tensions, and cartilage is an avascular tissue by nature [43]. Hypoxia in fact plays a crucial role during the chondrocyte differentiation [43]. The latter fact has led to tissue engineers focusing on the endochondral ossification pathway to construct bone.

Much work has already been done to advance knowledge in the field of endochondral ossification. Almost a century ago, in 1920, Asami and Dock described how the process of endochondral ossification could explain bone formation in subcutaneous autotransplantation of ear cartilage in rabbits [44]. Later in the 30s and 40s, pioneers in tissue engineering discovered the effect of anterior hypophyseal extract on cartilage hypertrophy in dogs [45]. Most likely they observed increased cartilage hypertrophy by causing thyroid gland hypertrophy due to their hypophyseal extract injections. The enlarged gland increased production of thyroid hormone, which is known for its stimulation of endochondral ossification. Other hormones were also studied for their effect on endochondral ossification, such as testosterone, panthothenic acid, and riboflavine [46, 47]. These early studies describe the work of last century's pioneers, investigating endochondral ossification in animal models.

It was back in the 70s and 80s when scientists revisited the osteogenic potency of cartilage even when transplanted heterotopically. After autologous and allogeneic transplantation of a rat's patella to a variety of sites (i.e. muscle, thyroid, testis, anterior chamber of the eye) ossification occurred, sketching the first theories about endochondral bone formation in sites embryologically formed through intramembranous ossification or not associated with bone et al [48]. Thus, this would favor the feasibility of regeneration of maxillofacial bones via the endochondral approach.

Eventually, in 1976, the first *in vitro* model of hypertrophic chondrocytes from the chick limb bud mesenchymal cells with subsequent mineralization of the matrix was published [49]. Further research on such *in vitro* models led to an increased understanding in the signals and pathways that are involved in endochondral ossification throughout the following decades, leading to the use of human bone marrow-derived MSCs to mimic the process of endochondral bone formation [50, 51, 52, 53]. In 2006, for the first time, endochondral bone formation was established after subcutaneous implantation of chondrogenically differentiated human MSC aggregates [22]. Later, it was shown that both chondrogenic priming of human MSCs *in vitro* and *in vitro* induction of hypertrophy or mineralization prior to implantation could support endochondral bone formation *in vivo*, including the formation of marrow cavities [54, 55, 56, 57].

More recently, the endochondral bone regeneration potential of MSCs was established in bone defects. Van der Stok *et al.* created a 6 mm critical size femoral bone defect in athymic rats [58]. These defects were grafted with either human chondrogenically differentiated MSC pellets or undifferentiated MSC pellets. Micro-CT scans showed that chondrogenic MSC pellets resulted in significantly more bone formation than undifferentiated MSC pellets. Histology revealed the presence of hypertrophic chondrocytes, osteoclastic resorption and

vascularization, typical for endochondral ossification. However, the amount of bone regeneration was highly MSC donor dependent [58]. In the same year, chondrogenically primed rat MSCs were seeded on degradable PLGA scaffolds to regenerate a 15 mm long critical size femur defect in rats. X-ray and histological examinations confirmed both intramembranous and endochondral origin of the regenerated bone [59].

A clinical, maxillofacial example of endochondral ossification can be found in patients who undergo costo-chondral graft procedure of the temporo-mandibular joint. [60–62] The chondral part of the graft has the tendency to increase in length through endochondral ossification after the transplantation to mandible in growing patients. It is therefore generally advised to transplant a rib with a shorter chondral part to avoid unwanted growth [60]. Another example is seen in some cases where ankylosis of the reconstructed temporo-mandibular joint develops due to ossification of the chondral part [61, 62].

To conclude, the way to engineer endochondral bone from natural or engineered cartilaginous tissues has been paved in the past century. It has led to the *in vivo* successes shown by recent publications. Collectively, the robustness of the approach has been well-established, showing that chondrogenically primed MSCs, all or not combined with a carrier material, can induce endochondral ossification at both ectopic and orthotopic sites. Future challenges include the scale-up of construct size, translation to clinically applicable protocols and products and exploration of endochondral bone regeneration from devitalized cartilage constructs [63, 64].

Maxillofacial endochondral bone regeneration

The use of MSCs for bone regeneration is associated with the invasiveness of the harvesting procedure, low harvested cell numbers, limited expansion capacity, heterogeneity in differentiation and donor site morbidity. These disadvantages have stimulated a search for alternative cell sources and the assessment of MSC-like cell populations from multiple adult anatomical locations, including tissues in the craniomaxillofacial area. In the oral and facial region, stem cells originating from the neural crest (NCSCs) can be found. Possible sources of NCSCs in the craniofacial area are the skin of the scalp, hair follicles, the cornea, olfactory mucosa, respiratory mucosa, hard palate, oral mucosa, dental pulp, dental follicles and the periodontal ligaments [65]. Since the embryonic neural crest plays a crucial role in the development of progenitor cells responsible for maxillofacial osteogenesis, postnatal stem cells of neural crest origin could be an attractive candidate in craniofacial bone regeneration. Hypothetically, these cells could maintain their intrinsic potential to form craniomaxillofacial tissues. Indeed, adult NCSCs undergo self-renewal and show the capacity to differentiate into ectodermal and mesodermal cell types [66]. The characteristics, the embryonic neural crest origin, and the clinical potential of NCSCs harvested from various craniofacial tissues are reviewed elsewhere [66].

The NCSC population residing in the dental pulp has been studied extensively with respect to its differentiation potential into mineralizing cell types. Gronthos *et al.* hypothesized that a progenitor population for the dentin-producing odontoblasts is present inside the adult

pulp tissue with a plasticity beyond their natural odontogenic differentiation [67]. Such multipotent stem cell populations have been identified in the human dental pulp of both permanent and exfoliated deciduous teeth, and are termed dental pulp stem cells (DPSCs) and stem cells from human exfoliated deciduous teeth (SHEDs), respectively [67, 68]. Pulp tissue from permanent teeth, especially third molars, is readily available since third molar extraction is a routine clinical procedure. As this procedure is minimally invasive for the patient, the dental pulp represents an easy and accessible source for stem cell harvesting. Human DPSCs have been compared to MSCs extensively since their first isolation [67, 69, 70, 71, 72, 73, 74, 75, 76, 77]. DPSCs meet the requirements that define human MSCs, as have been established previously for MSCs [18, 78]. They adhere to plastic in standard culture conditions, express the correct surface antigens, while lacking others, and are able to differentiate into osteoblasts, adipocytes and chondrocytes *in vitro* (Zhang et al., 2006) [67, 79, 80]. Although DPSCs and MSCs appear to be similarly characterized, they display differences in other cell properties. Interestingly, human DPSCs exhibit a higher proliferation rate and colony forming efficiency than MSCs [67, 69, 72, 73, 74, 76, 77]. DPSC colonies contain a higher fraction of prolonged highly active proliferating cells compared to MSC colonies [72]. During long-term *in vitro* culture for up to 9 passages, DPSCs maintain their normal karyotype without any signs of genetic instability[81].

To determine the optimal cell source for maxillofacial bone regeneration, an important criterium is the degree, in which cells undergo *in vitro* chondrogenic and osteogenic differentiation under stimulatory culture conditions. So far, studies comparing the potential of human DPSCs and MSCs regarding the extent of their *in vitro* osteogenic differentiation have been made, with contradicting results [69, 70, 74, 82]. A higher osteogenic potential of DPSCs was verified by increased gene expression of osteocalcin, ALP, osteonectin and osterix , and more mineralization [69, 74]. On the contrary, MSCs compared to DPSCs displayed higher expression levels of osteogenic differentiation genes BMP-4 and Tuft1 [82]. Thus far, the chondrogenic differentiation potential of MSCs and DPSCs has been compared in few studies [70, 83]. Here, MSCs showed significantly better chondrogenic potential than DPSCs as demonstrated by higher collagen type II gene expression [70]. However, this study applied chondrogenic culture conditions that are commonly used for MSCs but may be suboptimal when used on neural crest derived stem cells. The optimal stimulation protocol for various cell types to induce chondrogenesis is still elusive [84]. For example, the different effects of growth factors from the TGF- β superfamily, alone or combined, on chondrogenesis have been reported for MSCs and adipose tissue derived stem cells. Likewise, it is expected that chondrogenesis of DPSCs requires extensive fine-tuning with respect to the chosen growth factors.

Undifferentiated DPSCs and BM-MSCs exhibit comparable basal gene expression patterns [75]. This includes the expression of genes associated with bone extracellular matrix and genes coding for growth factors that are involved in the induction of bone formation [75]. This expression profile, in the absence of any differentiation stimulus, might be suggestive of the intrinsic capacity of both cell populations to form mineralized tissues. Indeed, the

capability of non-stimulated MSCs to form bone in subcutaneous implantation models has been demonstrated extensively, in which the intramembranous and endochondral origin of the generated ectopic bone can be recognized [85, 86]. On the other hand, *in vivo* implanted undifferentiated DPSCs can form tissue resembling the pulp-dentin complex and bone [67, 87, 88, 89, 90]. Interestingly, also some spontaneous *in vivo* chondrogenic potential of non-induced DPSCs has been published. In particular, chondrocytes were found to be present next to osteocytes and adipocytes within recipient subcutaneous tissue, ten weeks post-transplantation of human DPSCs seeded on a calcium phosphate/PLGA carrier [89]. Furthermore, transplantation of rat DPSC pellets combined with a gelatin sponge not only gave rise to woven bone tissue and dentin-like structures after two weeks, but also cartilage tissue was formed in some cases [91]. The formation of cartilaginous tissue was also demonstrated for human DPSCs that were subcutaneously transplanted in new born mice for only two weeks [92]. Whether the cartilage tissue formed in these studies is stable or a temporary manifestation as seen in endochondral ossification, remains to be elucidated. A crucial aspect for cells used in bone regeneration via the endochondral pathway is their potential to terminally differentiate towards hypertrophic chondrocytes. This feature is well established for MSCs, but has yet to be demonstrated for DPSCs. Nevertheless, the gene and protein expression of the hypertrophic chondrocyte marker, collagen type X, by DPSC pellets was confirmed *in vitro*, suggesting a potential of DPSCs for endochondral bone regeneration [22, 51, 93, 94].

The repair of craniofacial bone defects by implantation of DPSCs has been verified in various animal models and one clinical study, all demonstrating substantial regeneration of vascularized bone [95, 96, 97, 98, 99, 100, 101]. Studies comparing the regenerative potential of canine DPSCs versus MSCs in mandibular bone defects showed significantly enhanced regeneration over time compared to the empty defect, but not between the DPSC and MSC groups [102, 103]. The next steps towards clinical translation would include optimization of DPSC pre-stimulation prior to implantation and proof-of-concept studies showing adequate craniofacial bone tissue regeneration while adhering to protocols suitable for clinical application (Advanced Therapy Medicinal Products).

The ability of adult stem cells of different embryonic origin to regenerate bone might be determined by their Hox-status. Hox-genes are expressed during development amongst the embryonic axis, providing cells with a positional identity. One experiment showed that tibia-derived *Hoxa11*-positive MSCs were not able to form bone after heterotopic implantation in a mandibular defect. However, mandible-derived *Hoxa11*-negative NCCs were able to form bone after heterotopic implantation in a tibial defect. Gene mapping showed the *Hoxa11*-positive tibial MSCs were not able to change their Hox-status, whereas the *Hoxa11*-negative mandible NCCs were able to alter their Hox-status to match the Hox-status of the heterotopic tibial environment [104]. The ability to change Hox-status hints on the plasticity of *Hoxa11*-negative stem cells, such as NCCs, to be potentially exploited for heterotopic bone tissue engineering.

In conclusion, DPSCs display an MSC-like nature. DPSCs have a common embryonic origin with various craniofacial skeletal elements, are readily accessible, possess a high proliferative capacity, osteogenic and chondrogenic differentiation potential, ability to restore craniofacial bone defects in animal models, and have the ability to adapt their Hox-status to the transplant environment, making DPSCs an attractive alternative for MSCs to be further explored in the endochondral route for craniofacial bone regeneration.

DISCUSSION AND CONCLUSION

Three properties associated with the ideal bone construct, osteoinductivity and osteoconductivity and absence of triggering an immune response associated with transplant failure, can be found in autologous bone grafts, the current gold standard bone substitute. Nevertheless, autologous bone transplantation, though very effective, is associated with donor site morbidity, prolonged operation time and hospital stay, and is limited in quantity. Therefore, in the past decades, the search for a suitable replacement for the current golden standard has led to a myriad of possibilities to reconstruct bone defects in the facial skeleton and skull. The present review is providing an overview of the potential endochondral bone formation as an alternative in reconstructive surgery of critical size defects in the craniofacial skeleton. Early research in tissue engineering using intramembranous ossification, or direct bone formation, showed promising results *in vitro*. However, the clinical translation showed limited success due to construct avascularity as the limiting factor for the creation of larger constructs. Recent research on endochondral bone formation in animals has shown its potential in clinical use, proving endochondral ossification to be an interesting pathway to explore in future research.

During human development most of the human skeleton is formed via endochondral bone formation. However, the majority of the craniofacial bones are formed through intramembranous ossification. Nevertheless, endochondral bone formation is present during the development of (amongst others) the mandibular collum, base of the skull and temporal bones. Although endochondral bone formation in the craniofacial skeleton is limited to prementioned regions, it is a native pathway in the growing human face and skull. Further, healing of craniofacial bone trauma is similar to that of the skeletal long bones. Depending on the type and location of the fracture and its mechanical environment, endochondral bone formation can be found in healing craniofacial fracture sites. Together, endochondral bone formation is a natural mechanism of bone formation, next to the intramembranous route, that can be found in the craniofacial region in development and fracture healing. This makes the endochondral ossification pathway a feasible option for bone regenerative strategies for maxillofacial applications [23].

Stem cells sources in the craniofacial region, such as DPSCs, have shown a higher proliferation potential than MSCs. Potentially, these stem cell sources lead to a higher final

cell yield, and with that the possibility to regenerate larger defects. Another benefit of these DPSCs is their embryological link with the craniofacial region. The facial bones and the skull are formed after condensation of embryonic neural crest cells. Additionally, uncommitted multipotent stem cells of neural crest origin are known to remain in the adult after embryogenesis is complete. Potentially, these stem cells show a higher bone regenerative capacity of tissue that more closely resembles the craniofacial native bone morphology. Nevertheless, the potential of craniofacial stem cells for bone regeneration through endochondral bone formation remains theoretical, awaiting confirmation by future studies. Next, several studies have indicated the importance of donor dependency of the outcomes of MSC-based endochondral bone regeneration when implanting human cells [55, 58, 105]. In light of clinical translation, either improved cell characterization and selection is required to ensure highly reproducible results, or implantation of allogeneic cells can be considered. The latter is an interesting option, considering the terminal fate of most hypertrophic chondrogenic cells that are implanted. The immunogenicity of implanted allogeneic cartilage is considered limited [106] and following conversion into bone, only a fraction of the implanted cells or tissue will survive after transdifferentiation in the patient [107]. Furthermore, isolation of stem cells from one donor to treat several patients will reduce treatment costs. Taking this a step further towards clinical application, devitalization of allogeneic constructs could be an interesting way to create off-the-shelf allogeneic endochondral therapies. Recently, the effectiveness of devitalization of chondrogenically differentiated MSCs was shown by timed induction of apoptosis and by decellularization of hypertrophic chondrogenic constructs [63, 64]. Based on this approach, clinical application may come within reach. However, scale-up of the construct size to clinically relevant dimensions, whilst retaining its osteoinductive properties throughout the full size of the construct, will remain a major challenge to be conquered in the near future. An important determinant of the success of this approach may turn out to be the immune system. Until now, the feasibility of endochondral bone formation with MSCs was foremost shown in xenogeneic immuno-incompetent rodent models. Only two studies have addressed implantation of allogeneic constructs in rats [54, 59]. Nevertheless, it remains to be elucidated whether the intact immune system is indeed an important aspect that can influence the outcome of the various options for the bone regenerative process [108].

Concluding, taking the endochondral route to craniomaxillofacial regeneration is a logical approach. It mimics the natural reparative mechanisms and also the developmental process of part of the bones. Local adult neural crest-derived stem cells hold potential for restoration of craniomaxillofacial bone defects. Whether they can be employed for the endochondral approach remains to be demonstrated but their behavioral similarity to MSCs holds great promise.

REFERENCES

- [1] Spicer PP, Kretlow JD, Young S, et al. Evaluation of bone regeneration using the rat critical size calvarial defect. *Nature Protocols* 2012; 7: 1918–1929.
- [2] Simon F, Ketoff S, Guichard B, et al. Lower jaw reconstruction and dental rehabilitation after war injuries: The experience of Paul Tessier in Iran in the late 1980s. *Journal of Cranio-Maxillofacial Surgery* 2015; 43: 606–610.
- [3] van Gemert JTM, van Es RJJ, Rosenberg AJWP, et al. Free Vascularized Flaps for Reconstruction of the Mandible: Complications, Success, and Dental Rehabilitation. *Journal of Oral and Maxillofacial Surgery* 2012; 70: 1692–1698.
- [4] Murray JC. Gene/environment causes of cleft lip and/or palate. *Clin Genet* 2002; 61: 248–256.
- [5] Organisation WH. Global data on incidence of oral cancer (maps), http://www.who.int/oral_health/publications/cancer_maps/en/ (2002).
- [6] Casagrande L, Cordeiro MM, Nör S a., et al. Dental pulp stem cells in regenerative dentistry. *Odontology* 2011; 99: 1–7.
- [7] Greenberg A, Prein J, Ehrenfeld M, et al. Autogenous Bone Grafts in Maxillofacial Reconstruction. In: *Cranio-maxillofacial Reconstructive and Corrective Bone Surgery*. Springer New York, pp. 295–309.
- [8] Turan A, Kostakoglu N, Tuncel U, et al. Scapular Bone Grafts: Good Options for Craniofacial Defects? *Ann Plast Surg*. Epub ahead of print 2014. DOI: 10.1097/SAP.0000000000000357.
- [9] Dimitriou R, Mataliotakis GI, Angoules AG, et al. Complications following autologous bone graft harvesting from the iliac crest and using the RIA: a systematic review. *Injury*; 42 Suppl 2: S3-15.
- [10] Nkenke E, Neukam FW. Autogenous bone harvesting and grafting in advanced jaw resorption: morbidity, resorption and implant survival. *Eur J Oral Implantol*; 7 Suppl 2: S203-17.
- [11] Papadopoulos NA, Schaff J, Bucher H, et al. Donor site morbidity after harvest of free osteofasciocutaneous fibular flaps with an extended skin island. *Ann Plast Surg* 2002; 49: 138–144.
- [12] Pototschnig H, Schaff J, Kovacs L, et al. The free osteofasciocutaneous fibula flap: Clinical applications and surgical considerations. *Injury* 2013; 44: 366–369.
- [13] Pogrel MA, Podlesh S, Anthony JP, et al. A comparison of vascularized and nonvascularized bone grafts for reconstruction of mandibular continuity defects. *J Oral Maxillofac Surg* 1997; 55: 1200–1206.
- [14] van Gemert JTM, van Es RJJ, van Cann EM, et al. Nonvascularized Bone Grafts for Segmental Reconstruction of the Mandible—A Reappraisal. *Journal of Oral and Maxillofacial Surgery* 2009; 67: 1446–1452.
- [15] Bahney CS, Hu DP, Miclau T, et al. The Multifaceted Role of the Vasculature in Endochondral Fracture Repair. *Frontiers in Endocrinology* 2015; 6: 4.
- [16] Ikada Y. Challenges in tissue engineering. *J R Soc Interface* 2006; 3: 589–601.
- [17] Xu QC, Wang ZG, Ji QX, et al. Systemically transplanted human gingiva-derived mesenchymal stem cells contributing to bone tissue regeneration. *International Journal of Clinical and Experimental Pathology*.
- [18] Dominici M, le Blanc K, Mueller I, et al. Minimal criteria for defining multipotent mesenchymal stromal cells. The International Society for Cellular Therapy position statement. *Cytotherapy* 2006; 8: 315–317.
- [19] Cancedda R, Giannoni P, Mastrogiacomo M. A tissue engineering approach to bone repair in large animal models and in clinical practice. *Biomaterials* 2007; 28: 4240–4250.

- [20] Westhrin M, Xie M, Olderooy MO, et al. Osteogenic differentiation of human mesenchymal stem cells in mineralized alginate matrices. *PLoS One* 2015; 10: e0120374.
- [21] Gawlitta D, Farrell E, Malda J, et al. Modulating endochondral ossification of multipotent stromal cells for bone regeneration. *Tissue Engineering - Part B: Reviews* 2010; 16: 385–395.
- [22] Pelttari K, Winter A, Steck E, et al. Premature induction of hypertrophy during in vitro chondrogenesis of human mesenchymal stem cells correlates with calcification and vascular invasion after ectopic transplantation in SCID mice. *Arthritis Rheum* 2006; 54: 3254–3266.
- [23] Nanci A. *Ten Cate's Oral Histology 8th edition*.
- [24] Hall BK. The neural crest as a fourth germ layer and vertebrates as quadroblastic not triploblastic. *Evol Dev* 2000; 2: 3–5.
- [25] Weston JA, Thiery JP. Pentimento: Neural Crest and the origin of mesectoderm. *Dev Biol*. Epub ahead of print 2015. DOI: 10.1016/j.ydbio.2014.12.035.
- [26] Santos F, McCall AA, Chien W, et al. Otopathology in Osteogenesis Imperfecta. *Otol Neurotol* 2012; 33: 1562–1566.
- [27] Yu YY, Lieu S, Hu D, et al. Site specific effects of zoledronic acid during tibial and mandibular fracture repair. *PLoS One* 2012; 7: e31771.
- [28] Mackie EJ, Ahmed YA, Tatarczuch L, et al. Endochondral ossification: how cartilage is converted into bone in the developing skeleton. *The international journal of biochemistry & cell biology* 2008; 40: 46–62.
- [29] Hunziker EB, Schenk RK, Cruz-Orive LM. Quantitation of chondrocyte performance in growth-plate cartilage during longitudinal bone growth. *J Bone Joint Surg Am* 1987; 69: 162–173.
- [30] Shapiro IM, Adams CS, Freeman T, et al. Fate of the hypertrophic chondrocyte: microenvironmental perspectives on apoptosis and survival in the epiphyseal growth plate. *Birth Defects Res C Embryo Today* 2005; 75: 330–339.
- [31] Hall BK. The neural crest and neural crest cells: discovery and significance for theories of embryonic organization. *J Biosci* 2008; 33: 781–793.
- [32] Einhorn TA, Gerstenfeld LC. Fracture healing: mechanisms and interventions. *Nat Rev Rheumatol* 2015; 11: 45–54.
- [33] Shapiro F. Bone development and its relation to fracture repair. The role of mesenchymal osteoblasts and surface osteoblasts. *Eur Cell Mater* 2008; 15: 53–76.
- [34] Teixeira AC, Luz JG, Araujo VC, et al. Healing of the displaced condylar process fracture: an experimental study. *J Craniomaxillofac Surg* 1998; 26: 326–330.
- [35] Caplan AI. Review: mesenchymal stem cells: cell-based reconstructive therapy in orthopedics. *Tissue Eng* 2005; 11: 1198–1211.
- [36] Krampera M, Pizzolo G, Aprili G, et al. Mesenchymal stem cells for bone, cartilage, tendon and skeletal muscle repair. *Bone* 2006; 39: 678–683.
- [37] Pittenger GL, Malik RA, Burcus N, et al. Specific fiber deficits in sensorimotor diabetic polyneuropathy correspond to cytotoxicity against neuroblastoma cells of sera from patients with diabetes. *Diabetes Care* 1999; 22: 1839–1844.
- [38] Caplan AI, Bruder SP. Mesenchymal stem cells: building blocks for molecular medicine in the 21st century. *Trends Mol Med* 2001; 7: 259–264.

- [39] Allay JA, Dennis JE, Haynesworth SE, et al. LacZ and interleukin-3 expression in vivo after retroviral transduction of marrow-derived human osteogenic mesenchymal progenitors. *Hum Gene Ther* 1997; 8: 1417–1427.
- [40] Meijer GJ, de Bruijn JD, Koole R, et al. Cell based bone tissue engineering in jaw defects. *Biomaterials* 2008; 29: 3053–3061.
- [41] Zhang Z. Bone regeneration by stem cell and tissue engineering in oral and maxillofacial region. *Front Med* 2011; 5: 401–413.
- [42] Volkmer E, Drosse I, Otto S, et al. Hypoxia in static and dynamic 3D culture systems for tissue engineering of bone. *Tissue Eng Part A* 2008; 14: 1331–1340.
- [43] Schipani E. Hypoxia and HIF-1alpha in chondrogenesis. *Ann N Y Acad Sci* 2006; 1068: 66–73.
- [44] Asami G, Dock W. EXPERIMENTAL STUDIES ON HETEROPLASTIC BONE FORMATION. *Journal of Experimental Medicine* 1920; 32: 745–766.
- [45] Silberberg M, Atherton H, Copher G. EFFECTS OF BOVINE ANTERIOR HYPOPHYSEAL EXTRACT ON URINARY BLADDER TRANSPLANTS IN YOUNG DOGS*: INCLUDING SOME OBSERVATIONS ON ITS EFFECTS ON ENDOCHONDRAL OSSIFICATION. *Annals of Surgery*. Epub ahead of print 1944. DOI: 10.1097/00000658-194410000-00021.
- [46] Levy BM, Silberberg R. Effect of Riboflavin Deficiency on Endochondral Ossification of Mice. *Experimental Biology and Medicine* 1946; 63: 355–360.
- [47] Levy BM, Silberberg M. Inhibition of Endochondral Ossification in Pantothenic Acid Deficiency. *Experimental Biology and Medicine* 1946; 63: 380–383.
- [48] Asch L, Asch G. [Ossification after transplantation of model cartilage in the rat patella]. *Archives d'anatomie, d'histologie et d'embryologie normales et experimentales* 1989; 72: 81–96.
- [49] Osdoby P, Caplan AI. The possible differentiation of osteogenic elements in vitro from chick limb mesodermal cells. I. Morphological evidence. *Dev Biol* 1976; 52: 283–299.
- [50] Ichinose S, Yamagata K, Sekiya I, et al. Detailed examination of cartilage formation and endochondral ossification using human mesenchymal stem cells. *Clin Exp Pharmacol Physiol* 2005; 32: 561–570.
- [51] Johnstone B, Hering TM, Caplan AI, et al. In vitro chondrogenesis of bone marrow-derived mesenchymal progenitor cells. *Exp Cell Res* 1998; 238: 265–272.
- [52] Mello MA, Tuan RS. High density micromass cultures of embryonic limb bud mesenchymal cells: an in vitro model of endochondral skeletal development. *In Vitro Cell Dev Biol Anim* 1999; 35: 262–269.
- [53] Yoo JU, Barthel TS, Nishimura K, et al. The chondrogenic potential of human bone-marrow-derived mesenchymal progenitor cells. *J Bone Joint Surg Am* 1998; 80: 1745–1757.
- [54] Farrell E, Both SK, Odorfer KI, et al. In-vivo generation of bone via endochondral ossification by in-vitro chondrogenic priming of adult human and rat mesenchymal stem cells. *BMC Musculoskelet Disord* 2011; 12: 31.
- [55] Janicki P, Kasten P, Kleinschmidt K, et al. Chondrogenic pre-induction of human mesenchymal stem cells on beta-TCP: enhanced bone quality by endochondral heterotopic bone formation. *Acta Biomater* 2010; 6: 3292–3301.

- [56] Jukes JM, Both SK, Leusink A, et al. Endochondral bone tissue engineering using embryonic stem cells. *Proc Natl Acad Sci U S A* 2008; 105: 6840–6845.
- [57] Scotti C, Tonnamelli B, Papadimitropoulos A, et al. Recapitulation of endochondral bone formation using human adult mesenchymal stem cells as a paradigm for developmental engineering. *Proc Natl Acad Sci U S A* 2010; 107: 7251–7256.
- [58] van der Stok J, Koolen MK, Jahr H, et al. Chondrogenically differentiated mesenchymal stromal cell pellets stimulate endochondral bone regeneration in critical-sized bone defects. *Eur Cell Mater* 2014; 27: 137–48; discussion 148.
- [59] Harada N, Watanabe Y, Sato K, et al. Bone regeneration in a massive rat femur defect through endochondral ossification achieved with chondrogenically differentiated MSCs in a degradable scaffold. *Biomaterials* 2014; 35: 7800–7810.
- [60] Elgazzar RF, Abdelhady AI, Saad KA, et al. Treatment modalities of TMJ ankylosis: experience in Delta Nile, Egypt. *International Journal of Oral and Maxillofacial Surgery* 2010; 39: 333–342.
- [61] Guyuron B, Lasa Jr. CI. Unpredictable growth pattern of costochondral graft. *Plast Reconstr Surg* 1992; 90: 880–889.
- [62] Shaker AA. The Use of Costochondral Grafts in the Management of Temporomandibular Joint Ankylosis. *Plast Reconstr Surg* 2003; 27: 73–83.
- [63] Bourguine P, le Magnen C, Pigeot S, et al. Combination of immortalization and inducible death strategies to generate a human mesenchymal stromal cell line with controlled survival. *Stem Cell Res* 2014; 12: 584–598.
- [64] Cunniffe GM, Vinardell T, Murphy JM, et al. Porous decellularized tissue engineered hypertrophic cartilage as a scaffold for large bone defect healing. *Acta Biomater* 2015; 23: 82–90.
- [65] Kaltschmidt B, Kaltschmidt C, Widera D. Adult craniofacial stem cells: sources and relation to the neural crest. *Stem Cell Rev* 2012; 8: 658–671.
- [66] Kaltschmidt B, Kaltschmidt C, Widera D. Adult Craniofacial Stem Cells: Sources and Relation to the Neural Crest. *Stem Cell Reviews and Reports* 2012; 8: 658–671.
- [67] Gronthos S, Mankani M, Brahim J, et al. Postnatal human dental pulp stem cells (DPSCs) in vitro and in vivo. *Proc Natl Acad Sci U S A* 2000; 97: 13625–13630.
- [68] Miura M, Gronthos S, Zhao M, et al. SHED: stem cells from human exfoliated deciduous teeth. *Proc Natl Acad Sci U S A* 2003; 100: 5807–5812.
- [69] Abu Kasim NH, Govindasamy V, Gnanasegaran N, et al. Unique molecular signatures influencing the biological function and fate of post-natal stem cells isolated from different sources. *J Tissue Eng Regen Med* 2015; 9: E252-66.
- [70] Isobe Y, Koyama N, Nakao K, et al. Comparison of human mesenchymal stem cells derived from bone marrow, synovial fluid, adult dental pulp, and exfoliated deciduous tooth pulp. *Int J Oral Maxillofac Surg* 2016; 45: 124–131.
- [71] Koyama N, Okubo Y, Nakao K, et al. Evaluation of pluripotency in human dental pulp cells. *J Oral Maxillofac Surg* 2009; 67: 501–506.
- [72] Menicanin D, Bartold PM, Zannettino AC, et al. Identification of a common gene expression signature associated with immature clonal mesenchymal cell populations derived from bone marrow and dental tissues. *Stem Cells Dev* 2010; 19: 1501–1510.
- [73] Pierdomenico L, Bonsi L, Calvitti M, et al. Multipotent mesenchymal stem cells with immunosuppressive activity can be easily isolated from dental pulp. *Transplantation* 2005; 80: 836–842.

- [74] Ponnaiyan D, Jegadeesan V. Comparison of phenotype and differentiation marker gene expression profiles in human dental pulp and bone marrow mesenchymal stem cells. *Eur J Dent* 2014; 8: 307–313.
- [75] Shi S, Robey PG, Gronthos S. Comparison of human dental pulp and bone marrow stromal stem cells by cDNA microarray analysis. *Bone* 2001; 29: 532–539.
- [76] Suchanek J, Soukup T, Ivancakova R, et al. Human dental pulp stem cells— isolation and long term cultivation. *Acta Medica (Hradec Kralove)* 2007; 50: 195–201.
- [77] Tamaki Y, Nakahara T, Ishikawa H, et al. In vitro analysis of mesenchymal stem cells derived from human teeth and bone marrow. *Odontology* 2013; 101: 121–132.
- [78] Pittenger MF, Mackay AM, Beck SC, et al. Multilineage potential of adult human mesenchymal stem cells. *Science* 1999; 284: 143–147.
- [79] Perry BC, Zhou D, Wu X, et al. Collection, cryopreservation, and characterization of human dental pulp-derived mesenchymal stem cells for banking and clinical use. *Tissue Eng Part C Methods* 2008; 14: 149–156.
- [80] Woods EJ, Perry BC, Hockema JJ, et al. Optimized cryopreservation method for human dental pulp-derived stem cells and their tissues of origin for banking and clinical use. *Cryobiology* 2009; 59: 150–157.
- [81] Govindasamy V, Ronald VS, Totey S, et al. Micromanipulation of culture niche permits long-term expansion of dental pulp stem cells—an economic and commercial angle. *In Vitro Cell Dev Biol Anim* 2010; 46: 764–773.
- [82] Karaoz E, Demircan PC, Saglam O, et al. Human dental pulp stem cells demonstrate better neural and epithelial stem cell properties than bone marrow-derived mesenchymal stem cells. *Histochem Cell Biol* 2011; 136: 455–473.
- [83] Sternberg H, Murai JT, Erickson IE, et al. A human embryonic stem cell-derived clonal progenitor cell line with chondrogenic potential and markers of craniofacial mesenchyme. *Regen Med* 2012; 7: 481–501.
- [84] Puetzer JL, Petite JN, Lobo EG. Comparative review of growth factors for induction of three-dimensional in vitro chondrogenesis in human mesenchymal stem cells isolated from bone marrow and adipose tissue. *Tissue Eng Part B Rev* 2010; 16: 435–444.
- [85] Derubeis AR, Cancedda R. Bone marrow stromal cells (BMSCs) in bone engineering: limitations and recent advances. *Annals of biomedical engineering* 2004; 32: 160–5.
- [86] Ashton BA, Allen TD, Howlett CR, et al. Formation of bone and cartilage by marrow stromal cells in diffusion chambers in vivo. *Clinical orthopaedics and related research* 1980; 294–307.
- [87] Graziano A, d'Aquino R, Laino G, et al. Human CD34+ stem cells produce bone nodules in vivo. *Cell Prolif* 2008; 41: 1–11.
- [88] Gronthos S, Brahimi J, Li W, et al. Stem cell properties of human dental pulp stem cells. *J Dent Res* 2002; 81: 531–535.
- [89] Morito A, Kida Y, Suzuki K, et al. Effects of basic fibroblast growth factor on the development of the stem cell properties of human dental pulp cells. *Arch Histol Cytol* 2009; 72: 51–64.
- [90] Otaki S, Ueshima S, Shiraishi K, et al. Mesenchymal progenitor cells in adult human dental pulp and their ability to form bone when transplanted into immunocompromised mice. *Cell Biol Int* 2007; 31: 1191–1197.
- [91] Yu J, He H, Tang C, et al. Differentiation potential of STRO-1+ dental pulp stem cells changes during cell passaging. *BMC Cell Biol* 2010; 11: 32.
- [92] Stevens A, Zuliani T, Olejnik C, et al. Human dental pulp stem cells differentiate into neural crest-derived melanocytes and have label-retaining and sphere-forming abilities. *Stem Cells Dev* 2008; 17: 1175–1184.

- [93] Mackay AM, Beck SC, Murphy JM, et al. Chondrogenic differentiation of cultured human mesenchymal stem cells from marrow. *Tissue Eng* 1998; 4: 415–428.
- [94] Dai J, Wang J, Lu J, et al. The effect of co-culturing costal chondrocytes and dental pulp stem cells combined with exogenous FGF9 protein on chondrogenesis and ossification in engineered cartilage. *Biomaterials* 2012; 33: 7699–7711.
- [95] Ahmeti H, Maslehaty H, Petridis AK, et al. Extensive growth of an anaplastic meningioma. *Case reports in neurological medicine* 2013; 2013: 527184.
- [96] Kuo T, Lee S-Y, Wu H-D, et al. An in vivo swine study for xeno-grafts of calcium sulfate-based bone grafts with human dental pulp stem cells (hDPSCs). *Materials science & engineering C, Materials for biological applications* 2015; 50: 19–23.
- [97] Maraldi T, Riccio M, Pisciotta A, et al. Human amniotic fluid-derived and dental pulp-derived stem cells seeded into collagen scaffold repair critical-size bone defects promoting vascularization. *Stem Cell Res Ther* 2013; 4: 53.
- [98] Petridis X, Diamanti E, Trigas Gc, et al. Bone regeneration in critical-size calvarial defects using human dental pulp cells in an extracellular matrix-based scaffold. *J Craniomaxillofac Surg* 2015; 43: 483–490.
- [99] Riccio M, Maraldi T, Pisciotta A, et al. Fibroin scaffold repairs critical-size bone defects in vivo supported by human amniotic fluid and dental pulp stem cells. *Tissue Eng Part A* 2012; 18: 1006–1013.
- [100] Pisciotta A, Riccio M, Carnevale G, et al. Human serum promotes osteogenic differentiation of human dental pulp stem cells in vitro and in vivo. *PLoS One* 2012; 7: e50542.
- [101] Giuliani A, Manescu A, Langer M, et al. Three years after transplants in human mandibles, histological and in-line holotomography revealed that stem cells regenerated a compact rather than a spongy bone: biological and clinical implications. *Stem Cells Transl Med* 2013; 2: 316–324.
- [102] Ito K, Yamada Y, Nakamura S, et al. Osteogenic potential of effective bone engineering using dental pulp stem cells, bone marrow stem cells, and periosteal cells for osseointegration of dental implants. *Int J Oral Maxillofac Implants* 2011; 26: 947–954.
- [103] Yamada Y, Ito K, Nakamura S, et al. Promising cell-based therapy for bone regeneration using stem cells from deciduous teeth, dental pulp, and bone marrow. *Cell Transplant* 2011; 20: 1003–1013.
- [104] Leucht P, Kim J-B, Amasha R, et al. Embryonic origin and Hox status determine progenitor cell fate during adult bone regeneration. *Development (Cambridge, England)* 2008; 135: 2845–54.
- [105] Farrell E, van der Jagt OP, Koevoet W, et al. Chondrogenic Priming of Human Bone Marrow Stromal Cells: A Better Route to Bone Repair? *Tissue Engineering Part C: Methods* 2009; 15: 285–295.
- [106] Arzi B, DuRaine GD, Lee CA, et al. Cartilage immunoprivilege depends on donor source and lesion location. *Acta Biomaterialia* 2015; 23: 72–81.
- [107] Yang G, Zhu L, Hou N, et al. Osteogenic fate of hypertrophic chondrocytes. *Cell Res* 2014; 24: 1266–1269.
- [108] Kovach TK, Dighe AS, Lobo PI, et al. Interactions between MSCs and immune cells: implications for bone healing. *Journal of immunology research* 2015; 2015: 752510.



CHAPTER 7

General discussion

GENERAL DISCUSSION, CONCLUSION AND FUTURE PERSPECTIVES

The Wilhelmina Children's Hospital cleft team (WCH UMC Utrecht cleft team) which is part of the University Medical Center Utrecht (UMC Utrecht, the Netherlands) is part of a Dutch Federation of University Medical Centers (NFU), an accredited center of excellence and a referral center for Cleft disorders of the lip, alveolar ridge and palate (CLP).

Patients with cleft lip and palate and patients with clefts as part of a syndrome are referred to and treated in the UMC Utrecht. The results of surgical and orthodontic treatment of children with bilateral clefts are subject of this thesis. Bilateral clefts differ from unilateral clefts: tissue defects are more severe and from birth on, the premaxilla protrudes and curls out. Closure of the lip at three months of age influences the position of the premaxilla. As growth continues, the premaxilla may be twisted, making closure of the nasal layer of the alveolar cleft and reconstruction of the alveolar ridge with an autologous bone graft difficult.

REVIEW OF LITERATURE, CURRENT RESULTS AND COMPLICATIONS

Chapter 2

In the review study about the management of the premaxilla in the treatment of the alveolar cleft it became obvious that current treatment is mainly based on expert opinions. As bilateral clefts are relatively rare (incidence of 1 in 5000 births), the majority of studies is based on unilateral clefts. It is important to realize that a bilateral cleft is not a combination of two unilateral clefts. This thesis underscores that the treatment of bilateral clefts is therefore different from the unilateral cleft treatment. Both lip, palatal and alveolar cleft closures are different from unilateral cleft repair.

In literature evidence based comparative studies in cleft surgery are scarce. The encountered literature consists of retrospective cohort studies in which results are described meticulously within one cleft team.

Timing of correction of the displaced premaxilla is discussed in various articles.

Firstly, a correction of the position of the premaxilla can be done early at an age before eight years with orthopedic and orthodontic procedures and devices. At very early age for example nasal-alveolar molding (NAM) can be used. When patients have become older orthodontic devices are used. Surgical correction before the age of eight can be another approach [1, 2]. However, care must be taken with this approach. For a surgical correction of the premaxilla an osteotomy of the premaxilla has to be carried out in the vomerine suture which is responsible for the maxillary growth [3]. If an osteotomy of the premaxilla is done at the same time as closure of the lip around 2.5 months of age, growth retardation of the midface is to be expected [4]. Therefore, an osteotomy of the premaxilla should be postponed until after the age of six when 90% of the midfacial growth is complete [5].

The more common approach nowadays is early or late secondary closure of the cleft combined with and osteotomy of the premaxilla, ideally done between the age of eight and

twelve years. Using this approach, the position of the premaxilla can be corrected and the alveolar cleft can be closed in the same procedure. Timing of this procedure is dependent on the eruption of the canines or sometimes the lateral incisors. If the roots have developed by three-quarters, surgery is imperative in order to facilitate these canines to erupt into newly formed bone [6]. During surgery watertight closure of nasal and oral layers are most important to prevent wound dehiscence and loss of the bone graft.

Besides growth retardation, other complications mentioned are: loss of bone graft due to infection, persisting mobility of the premaxilla, persisting fistulas and avascular necrosis of the premaxilla after osteotomy. Prevention of these complications is closely related to the preparation, planning and the surgery itself. Considering these points, early secondary alveolar bone grafting (SABG) is preferably done in combination with a premaxilla osteotomy (PO) before eruption of the canine, to ensure adequate repositioning and watertight closure of the cleft.

TIMING OF THE CLOSURE

Chapter 3

The protocol used by the Department of Maxillofacial surgery in the UMC Utrecht for repair of the alveolar cleft includes the repositioning of the premaxilla with an osteotomy and the grafting of the alveolar defect with an autologous bone graft before the eruption of the canine. The timing between age 8-12 year is defined as “secondary alveolar bone grafting”. Patients that were treated in our department between 2004 and 2014 were analysed for pre-operative parameters included age, donor site, race, gingival health, bone quality around cleft-related teeth, premaxilla position, graft timing, presence of canines and lateral incisors in the cleft, and presence of deciduous teeth around the cleft area.

In this chapter it is demonstrated that bone quality around the cleft, preoperative malposition of the premaxilla and an older age at surgery are related to the occurrence of complications. In the logistic regression analysis preoperative position of the premaxilla had a significant relation to complications. Appropriate orthodontic preparation is therefore an important factor for a successful procedure. The study in chapter three shows that in 42% of the cases with a displaced premaxilla later revision surgery was needed, according to earlier literature [7, 8].

A displaced premaxilla makes access to the nasal layer and tension-free watertight closure difficult. An osteotomy gives access to the nasal layer for watertight closure of the nasal layer. However, closure of the oral layer is difficult after an osteotomy of the premaxilla which was severely twisted before surgery as the soft tissue still has its original anatomy. Sindet-Pedersen and Enemark reported 37.5% of complications and found that delayed bone healing is mostly related to infections in the grafted region [9].

The present study demonstrates that early secondary alveolar bone grafting yields less complications than late secondary grafting: closure of the alveolar cleft at an older age than

12 years gave more complications. Timing is one of the essentials in securing good results and differs from patient to patient: patients treated at a younger age, before eruption of the canine, have less complications. In literature this concept has been widely promoted as early as in the eighties and is still shown in more recent studies [9, 10, 11].

Poor bone quality around the roots adjacent to the cleft was found to be a significant factor for developing postoperative complications. We have to be cautious interpreting this result as the intra-rater weighted kappa was 0.27. An explanation may be a more direct interaction between bone transplant and the root of the canine or lateral incisor if present. A bone transplant that has been positioned next to a uncovered dental root instead of acceptor bone may not integrate and will be prone to a partial or even complete loss. Poor quality of bone around the cleft may be a predictor for complications and should be considered when closing the alveolar cleft. Pre-existing poor alveolar bone quality of the premaxilla around the erupted central incisors is an inevitable problem. It is not yet known if preoperative orthodontics may play a beneficial or rather an unfavorable role as roots may be positioned outside the bone.

In the present study we see a significant number of patients (26) being treated with late secondary alveolar bone grafting. We have to keep the disadvantages of this procedure in mind and pay more attention to timely planning of the secondary alveolar bone grafting and premaxilla osteotomy procedure.

GROWTH, DENTAL ASPECTS OF THE ALVEOLAR CLEFT AND FUTURE OF BONE GRAFTS

MAXILLARY GROWTH

Chapter 4

Together with speech, growth is one of the most important parameters in CLP surgery and during decennia a subject of research and debate. In non-operated patients with BCLP the premaxilla starts with a protrusion. However, at the end of the midfacial growth a merely normal growth of the premaxilla is seen [12]. On the other hand, some researchers suggest an inherent lack of midfacial growth potential in patients with BCLP [13]. Padwa et al. studied the timing of the alveolar bone grafting procedure compared to midface growth [5]. They concluded that a premaxilla osteotomy can be done at an early age without compromising growth. The patients with bilateral clefts in our center were all treated with a secondary alveolar bone grafting. The mean age of this patient group was 11.73 years.

In chapter four, this patient group was evaluated for midfacial growth parameters, and a comparison was made with literature using the BAURU-Yardstick, a modification of the GOSLON-Yardstick for unilateral clefts to suit patients with BCLP, [14]. Using the BAURU-Yardstick Bartzela et al. made a comparison between centers with different treatment protocols. In BCLP patients secondary alveolar bone grafting (SABG) can be done with or

without an osteotomy of the premaxilla in combination with a repositioning of the premaxilla [15]. This study found no differences in the BAURU-Yardstick scores between centers using different treatment protocols especially with and without an osteotomy of the premaxilla. In chapter four we compared our data with the data presented in the study by Bartzela et al. and also found no differences in the BAURU-yardstick scores and the comparative scores of our center.

Repositioning of the premaxilla is needed to position the premaxilla in a just and positive sagittal overbite and vertical overjet. Another advantage of this procedure is to ensure a watertight closure of the nasal floor because access to the nasal floor is made easier after a premaxilla osteotomy. A watertight closure of the nasal floor reduces the possibility of an infection of the bone graft post-operatively. Nevertheless, the osteotomy is carried out in a part of the maxilla that is partially responsible for the midfacial growth in the vomerine suture, therefore this osteotomy may negatively affect sagittal growth of the (pre)maxilla. The study in chapter four revealed an important Point A – Point Nasion – Point B (ANB) angle-value in cephalometric analysis. If the ANB angle was less than 6° already before surgical treatment a 78% chance is present that there will be a reversed sagittal frontal relation at a later age which is an indication for a later le Fort I osteotomy. It is important to keep this in mind when treating patients with BCLP. As these patients are treated orthodontically for several years, it might be wise to remember these numbers whilst treating these patients. For instance, by informing them about treatment options and maybe by giving them an orthodontic “time-out” for a few years before starting the orthodontic preparation for the orthognathic surgery. In line with this conclusion there is no catch-up growth seen in the present patients group: patients with a retrusive midface at the age of 11-12 years, will probably need a (bi)maxillary osteotomy at the age of eighteen. It might be wise to consider future research on this topic by means of a prospective multicenter study with different treatment protocols for the treatment of patients with bilateral cleft lip and palate.

Answering research questions

Is timing of secondary alveolar bone grafting together with premaxilla osteotomy between 8-12 year of age using the developmental stage of the root of the canine a guidance for timing a good strategy?

Timing should be based on the development of the root of the lateral incisor and/or the root of the canine that should have developed no more than 3/4. Early secondary alveolar bone grafting should be planned to prevent complications.

In bilateral cleft lip and palate, patient's growth might not only be disturbed due to surgery. Are other factors involved?

In our center the results are comparable with the study by Bartzela et al. Growth after closure of lip, soft and hard palate, and after closure of the bilateral alveolar cleft with a premaxilla osteotomy in our center is comparable with other centers [15]. It is difficult to pin-point the other factors, as there are many confounders in this retrospective study design.

Are there parameters in the BAURU Yardstick and in the cephalometric analysis for bilateral cleft lip and palate patients that can be used to predict midfacial growth of the Bilateral Cleft Lip Palate Patients at an age between 8 and 12 years?

During the period of retrospective observation, a gradual decrease of the ANB angle value was found. We found a negative correlation between the pre-operative SABG ANB angle and end-point BAURU scores, meaning a lower angle will result in a worse BAURU score.

A cut off point was estimated. An ANB angle value of 6° or less gives a 78% change for a negative overjet and need for a Le Fort I osteotomy later on.

FINAL DENTO MAXILLARY RESULTS

Chapter 5

Today, cleft lip and palate treatment research addresses standardizing cleft care and the evaluation of treatment protocols between cleft centers. Examples are Scandcleft and Eurocleft [16, 17]. These studies analyse patient groups in different hospitals with standardized questionnaires, scoring systems, dental casts, and x-rays. This research is helpful in getting an overview of the cleft lip care in general, between countries and on different elements of cleft surgery. For example, the residual bone height after secondary alveolar bone grafting and measurement of growth disturbances. This thesis aims to investigate the clinically relevant outcome of the secondary alveolar bone grafting procedure, not by only measuring the residual bone height but by addressing several dento-maxillary results. In analysing the dento-maxillary results, a scoring system which makes comparison possible, was missing. A new scoring system was created: the Dento-Maxillary Scoring System (DMSS). This system can be used to obtain a quick end-point analysis of each patient. The DMSS has not been validated yet as a new repeatable scoring system, but it has been built with validated parameters. It is designed for screening the dento-maxillary aspect of bilateral cleft lip and palate patients. Other dental scoring systems used for cleft lip and palate patients do exist, but these are not specially designed for cleft lip and palate analysis. Examples are the DMFT and OHIP scoring lists. Our cleft center obtained an overall score of on average 7.6 (standard deviation 2.2 with a median of eight).

Patients in this study were scored on what we think are clinically important parameters for failure or success of closure of the alveolar and palate cleft. The parameters are: persistent fistulas, residual bone height and the possibility to use the reconstructed bone in the cleft area for dental rehabilitation, and a proper orthognathic relationship. Of these patients 69% have a dento-maxillary outcome in which the originally interrupted maxillary dental arch had been reconstructed at cleft level with or patients' own teeth, or a fixated bridge, bridging the alveolar cleft, or with an implant. Nowadays, implants in the cleft region have good esthetics and function [18].

A percentage of 69% is considered a sufficient treatment result in bilateral cleft lip and palate cases. In the study it was demonstrated, that patients with fistulas, often resulting from a failed bone graft, are more likely to end up with removable prosthetics. Interestingly, graft failure is related to factors like age, lack of soft tissue during closure of the layers and reoperation of the alveolar cleft [19]. This shows the overall importance of an accurate planning and the optimal starting point. If one of the operative steps fails, it will be difficult to correct these failures and to achieve an end result comparable with an uncomplicated case. If all these parameters are correctly managed the likelihood of an optimal treatment result with an uninterrupted dental arch will be higher.

Answering research question

Does the Utrecht Bilateral Cleft Lip Palate Patients treatment protocol result in interconnected natural teeth over the grafted area without residual fistula and without prosthetic reconstructive dental implants, or dental appliances at age 18 years?

In this retrospective analysis it was demonstrated, that in 69% of the patients, an uninterrupted dental arch could be established. So the Utrecht Cleft team was not able to create an uninterrupted arch in more than 80% of the cases. We see room for improvement: In our study 16% residual fistulas were found, which is slightly more than the 11% by Scott et al. 2017 [20]. As there is a relation between the occurrence of fistula's and an interrupted arch as shown in chapter five, reduction of the fistula's is the first and probably the most effective way to improve the percentage of uninterrupted arches. Surgical principles as meticulous closure of the different layers, during SABG+PO will help reducing the number of fistulas. Reducing the number of interrupted arches can be solved by reducing the number of complications in SABG+PO. Early SABG+PO is probably the most efficient way to reduce the complications and thereby reducing persistent fistulas and interrupted dental arches. We are definitely in need of further prospective multi center studies.

THE FUTURE OF BONE GRAFTING

Chapter 6

The current golden standard of bone grafting in the treatment of patients with a bilateral cleft lip and palate is bone grafting with an autologous bone graft [21]. Various donor sites are available in these patients, most commonly used is the iliac crest or the mandibular symphysis. For a bone graft to be suitable for alveolar bone grafting the construct should be replaced by vital bone into which a tooth can erupt and/or orthodontically positioned [22]. In our center the mandibular symphysis was preferred as a donor site [23]. Although this method has proven itself in the past, some side effects are associated with this procedure: longer surgery time, donor site morbidity, and post-surgery pain. Therefore, there still is a search for a new bone construct. A new bone construct should have osteo-inductivity, osteo-conductivity and should not trigger an immune response which could

result in failure (infection, resorption) of the bone graft. In our department major research is done on the use of bone substitutes in unilateral cleft lip and palate patients with promising results leading to standard implication of this construct in the clinic [24].

In patients with bilateral cleft lip and palate closure of the mucosal layers is more difficult and therefore non vital bone constructs are more prone to infection and an inevitable failure of the grafting procedure.

The review in chapter six provides an overview of the potential endochondral bone formation as an alternative for reconstructions of critical size bone defects. Intramembranous bone formation provided promising results *in vitro*, however clinical translation has proven to be difficult as construct avascularity is a limiting factor. In endochondral bone formation the avascularity and hypoxia is the thriving factor [25]. In this approach stem cells are needed as a starting point; a promising source of stem cells are the dental pulp stem cells (DPSC's) harvested from the teeth. They have shown a higher proliferation potential in comparison with multipotent mesenchymal stromal cells (MSC's)[26]. Another suggested benefit of these cells is the embryological link with the craniofacial region. However all above mentioned is theoretical and have to be proven in future studies.

CONCLUSIONS

- Timing of repair of BCLP should be based on the development of the root of the lateral incisor and/or the root of the canine which should not have developed more than $\frac{3}{4}$.
- Late secondary alveolar bone grafting is associated with more complications after surgery in comparison with early secondary alveolar bone grafting.
- Growth retardation in the present study after closure of lip, soft and hard palate, and closure of the bilateral alveolar cleft with a premaxilla osteotomy is comparable with other centers.
- There was a decrease in SNA and ANB angle value over time, indicating a delayed growth of the maxilla.
- A correlation between a lower pre-operative ANB angle and a worse end-point BAURU score was found.
- Alveolar bone grafting together with premaxilla osteotomy is not a clinically relevant midfacial growth inhibiting factor in patients with BCLP, but prospective studies with standardized treatment protocols are needed for definite confirmation.
- An ANB angle value of 6° or less gives a 78% change for a negative sagittal frontal overjet at the age of 18 and need for a Le Fort I osteotomy.
- A Dento-Maxillary Scoring System is proposed for screening the dento-maxillary treatment results of bilateral cleft lip and palate patients.
- Using the Dento-Maxillary Scoring System, our cleft center obtained an overall score of 7.6 (SD 2.2 with a median of 8).
- The occurrence of fistulas post-operatively is related to an interrupted dental arch.

FUTURE PERSPECTIVES

Research in the field of treatment of patients with bilateral cleft lip and palate should be focused on meticulous registration at specific treatment moments. These moments have to be synchronized between centers in the Netherlands, preferably on an international scale. As the incidence of patients with bilateral cleft lip and palate is low, collaboration between research centers in the field of care for these patients is imperative. With the work of the International Consortium of Health Outcome Measurement (ICHOMS) a step is made towards standardization of follow up of treatment [27]. The next step should be the use of these data between centers to evaluate the outcome of treatment and, if possible, to improve outcomes. Nowadays different specialists still have different views about the treatment protocol for these patients, and this is seen in the differences between treatment protocols used by different cleft teams. Combining these data, it most probably will be possible to distil a treatment protocol which is best for speech, growth, facial morphology, oral function, cosmetic esthetics and patient satisfaction.

As seen in this thesis it is still difficult to analyze the midfacial growth pattern in these patients. This is due to the heterogeneity of mostly retrospectively analysed patient data. The specific factors influencing growth are not fully understood yet. Available research suggests influencing the timing of hard palate closure, the timing of alveolar bone grafting, pharyngeoplasty, and maybe also genetic factors. With modern radiological techniques like Cone Beam Computed Tomography (CBCT) with very low radiation doses, early and standard follow up using these scans will come within reach. CBCT scanning just after hard palate closure, before secondary alveolar bone grafting, one year after secondary alveolar bone grafting and at the end of follow up at the age of 17 is suggested.

This thesis has shown we should be self-critical as high complication rates are seen in the patients that were treated outside the preferred timing of bone grafting. Although it is our aim to treat all patients with early secondary alveolar bone grafting, twenty-six (41%) patients were treated with late secondary alveolar bone grafting. In this patient group a significant higher rate of complications was seen. In order to minimize the possibility of missing these patients' data for planning of the alveolar bone grafting a good collaboration between all specialists involved in the treatment is needed.

There is a need of intercollegiate knowledge exchange of surgical procedures between specialists involved in the multidisciplinary treatment of patients with bilateral cleft of lip and palate. Mutual consultations in this way can be held timely and treatment windows will not be missed.

Collaboration between specialists involved in the treatment of patients with cleft of lip and palate is generally arranged in multidisciplinary consultations. Possibly, future BCLP-surgery can also be done in collaboration, assuming every specialist has knowledge of every step involved in the treatment of patient with bilateral cleft of lip and palate.

REFERENCES

- [1] Shetty V, Vyas HJ, Sharma SM, et al. A comparison of results using nasopalveolar moulding in cleft infants treated within 1 month of life versus those treated after this period: Development of a new protocol. *International Journal of Oral and Maxillofacial Surgery* 2012; 41: 28–36.
- [2] Santiago PE, Schuster LA, Levy-Bercowski D. Management of the alveolar cleft. *Clinics in Plastic Surgery* 2014; 41: 219–232.
- [3] Heidbuchel KLWM, Kuijpers-Jagtman AM, Van't Hof MA, et al. Effects of early treatment on maxillary arch development in BCLP. A study on dental casts between 0 and 4 years of age. *Journal of Cranio-Maxillo-Facial Surgery* 1998; 26: 140–147.
- [4] Bishara SE, Olin WH. Surgical repositioning of the premaxilla in complete bilateral cleft lip and palate. *The Angle orthodontist* 1972; 42: 139–147.
- [5] Padwa BL, Sonis A, Bagheri S, et al. Children with repaired bilateral cleft lip/palate: Effect of age at premaxillary osteotomy on facial growth. *Plastic and Reconstructive Surgery* 1999; 104: 1261–1269.
- [6] Freihofer HPM, van Damme PA, Kuijpers-Jagtman AM. Early secondary osteotomy-stabilization of the premaxilla in bilateral clefts. *Journal of Cranio-Maxillofacial Surgery* 1991; 19: 2–6.
- [7] Koh KS, Kim H, Oh TS, et al. Treatment algorithm for bilateral alveolar cleft based on the position of the premaxilla and the width of the alveolar gap. *Journal of Plastic, Reconstructive and Aesthetic Surgery* 2013; 66: 1212–1218.
- [8] Rawashdeh MA, Telfah H. Secondary alveolar bone grafting: the dilemma of donor site selection and morbidity. *The British journal of oral & maxillofacial surgery* 2008; 46: 665–670.
- [9] Sindet-Pedersen S, Enemark H. Comparative study of secondary and late secondary bone-grafting in patients with residual cleft defects. Short-term evaluation. *International Journal of Oral Surgery* 1985; 14: 389–398.
- [10] Fahradyan A, Tsuha M, Wolfswinkel EM, et al. Optimal Timing of Secondary Alveolar Bone Grafting: A Literature Review. *Journal of Oral and Maxillofacial Surgery* 2019; 77: 843–849.
- [11] Miller LL, Kauffmann D, St John D, et al. Retrospective review of 99 patients with secondary alveolar cleft repair. *Journal of oral and maxillofacial surgery : official journal of the American Association of Oral and Maxillofacial Surgeons* 2010; 68: 1283–1289.
- [12] Diah E, Lo L-J, Huang C-S, et al. Maxillary growth of adult patients with unoperated cleft: answers to the debates. *Journal of plastic, reconstructive & aesthetic surgery : JPRAS* 2007; 60: 407–413.
- [13] Trotman CA, Ross RB. Craniofacial growth in bilateral cleft lip and palate: ages six years to adulthood. *The Cleft palate-craniofacial journal : official publication of the American Cleft Palate-Craniofacial Association* 1993; 30: 261–273.
- [14] Ozawa TO, Shaw WC, Katsaros C, et al. A new yardstick for rating dental arch relationship in patients with complete bilateral cleft lip and palate. *The Cleft palate-craniofacial journal : official publication of the American Cleft Palate-Craniofacial Association* 2011; 48: 167–172.
- [15] Bartzela T, Katsaros C, Shaw WC, et al. A longitudinal three-center study of dental arch relationship in patients with bilateral cleft lip and palate. *The Cleft palate-craniofacial journal : official publication of the American Cleft Palate-Craniofacial Association* 2010; 47: 167–174.
- [16] Semb G. The Scandleft project, <http://www.isrctn.com/ISRCTN29932826> (2016).

- [17] Shaw WC, Semb G, Nelson P, et al. The Eurocleft project 1996-2000: overview. *J Craniomaxillofac Surg* 2001; 29: 131-132.
- [18] Alberga JM, Stellingsma K, Meijer HJA, et al. Dental implant placement in alveolar cleft patients: a retrospective comparative study on clinical and aesthetic outcomes. *International Journal of Oral and Maxillofacial Surgery* 2020; 49: 952-959.
- [19] Bittermann GKP, van Es RJJ, de Ruiter AP, et al. Incidence of complications in secondary alveolar bone grafting of bilateral clefts with premaxillary osteotomy: a retrospective cohort study. *Clinical Oral Investigations* 2020; 24: 915-925.
- [20] Scott R, Scott J, Stagnell S, et al. Outcomes of 44 consecutive complete bilateral cleft lip and palate patients treated with secondary alveolar bone grafting and premaxillary osteotomy. *Cleft Palate-Craniofacial Journal* 2017; 54: 249-255.
- [21] Enemark H, Jensen J, Bosch C. Mandibular bone graft material for reconstruction of alveolar cleft defects: Long-term results. *Cleft Palate-Craniofacial Journal* 2001; 38: 155-163.
- [22] Janssen NG, de Ruiter AP, van Hout WMMT, et al. Microstructured β -Tricalcium phosphate putty versus autologous bone for repair of alveolar clefts in a goat model. *Cleft Palate-Craniofacial Journal* 2017; 54: 699-706.
- [23] Koole R. Ectomesenchymal mandibular symphysis bone graft: An improvement in alveolar cleft grafting? *Cleft Palate-Craniofacial Journal* 1994; 31: 217-223.
- [24] Janssen NG, Schreurs R, de Ruiter AP, et al. Microstructured beta-tricalcium phosphate for alveolar cleft repair: a two-centre study. *International Journal of Oral and Maxillofacial Surgery* 2019; 48: 708-711.
- [25] Schipani E. Hypoxia and HIF-1 α in chondrogenesis. In: *Annals of the New York Academy of Sciences*. 2006. Epub ahead of print 2006. DOI: 10.1196/annals.1346.009.
- [26] Gronthos S, Mankani M, Brahim J, et al. Postnatal human dental pulp stem cells (DPSCs) in vitro and in vivo. *Proc Natl Acad Sci U S A* 2000; 97: 13625-13630.
- [27] Bittar PG, Carlson AR, Mabie-DeRuyter A, et al. Implementation of a Standardized Data-Collection System for Comprehensive Appraisal of Cleft Care. *The Cleft palate-craniofacial journal : official publication of the American Cleft Palate-Craniofacial Association* 2018; 55: 1382-1390.



CHAPTER 8

Summary

Review of literature, current results and complications

In **chapter two** the literature is reviewed to compare treatment protocols for alveolar bone grafting with the current treatment protocol in The Wilhelmina Children's Hospital cleft team (WCH UMC Utrecht cleft team), part of the University Medical Center Utrecht (UMC Utrecht, the Netherlands). A consensus of best practice based on literature is formulated.

In Chapter three the current treatment protocol of Secondary Alveolar Bone Grafting (SABG) and premaxilla osteotomy at an age of 8-12 year in the WCH UMC Utrecht for BCLP is reviewed. Long-term results and complications are described retrospectively. The timing protocol using root development of the upper canine is analyzed.

Growth, dental aspects of the alveolar cleft and future of bone grafts

In Chapter four the maxillofacial growth of BCLP patients is compared with other studies on the growth of BCLP patients. The BAURU Yardstick in combination with cephalometrics is used to predict growth of the maxilla and to investigate the cause of growth disturbances in BCLP patients. A search for predictive factors for growth disturbance is part of chapter three.

In **Chapter five** the results of the Secondary Alveolar Bone Grafting and Premaxilla Osteotomy procedure are analysed on dento-maxillary level. An ideal treatment result at 18 year of age is formulated. A new Dento Maxillary Scoring System (DMSS) is proposed which provides a straightforward and easy-to-use tool for description and analysis of the overall dento-maxillary reconstruction at the end of treatment of BCLP patients.

Finally, in **Chapter six** a review is executed on the future of bone grafting. Until now autologous bone grafts from various donor sites are used. In the near future, it may be possible to create autologous bone constructs in laboratories.

Chapter One is an introduction to this study. In the Netherlands about 1 in 500 children is born with a cleft of lip and/or a cleft palate. In most cases the cleft is on one side of the mouth (unilateral cleft lip/palate, or UCLP), but about 1 in 5000 children is born with a cleft on both sides (bilateral cleft lip and palate, or BCLP). Bilateral cleft lip and palate patients are preferably treated in a tertiary center, such as the Wilhelmina Children's Hospital of University Medical Center Utrecht (WCH UMCU). This hospital treats BCLP patients in a multidisciplinary team of specialists in the fields of obstetrics, plastic surgery, maxillofacial surgery, orthodontics, dentistry, audiology, pediatric otolaryngology, speech pathology, occupational/feeding therapy, genetics and psychiatry. An important aspect of the treatment of BCLP patients is managing the position of the premaxilla and closure of the alveolar clefts. The clefts cause the premaxilla to be mobile as it is only apically fixed to the septal and vomerine bone. Handling of the position of the premaxilla in combination with the surgery to close the alveolar cleft is technically difficult. This study focusses on closing the alveolar clefts in BCLP patients, in combination with an osteotomy of the premaxilla and a secondary alveolar bone grafting (SABG), which means a three-layer-closure of the clefts using an autologous bone graft after nasal and palatal/buccal closure at age of 8-12 year. The outline of the study is:

- Review of the literature on management of the position of the premaxilla in BCLP.
- Analysis of the outcome of the SABG procedure in combination with premaxilla osteotomy in WCH UMCU.
- Analysis of the midfacial growth in BCLP patients treated in Utrecht, and comparison of the midfacial growth with patients treated in Goteborg, Nijmegen and Oslo.
- Analysis of the end result of the bone grafting procedure and orthodontic treatment from a clinical relevant perspective with a new Dento-Maxillary Scoring System.
- A look in the future of bone grafting.

Chapter Two reviews the literature on the management of the position of the premaxilla. A search of the literature yielded 16 relevant articles. These articles were included because they reported on timing and technique of procedures to correct the position of the premaxilla, on complications and/or surgical results and growth of the maxilla. The articles report various methods to correct the position of the premaxilla. The timing of the correction can be early primary (< 8 years), early and late secondary (8-12 years) and late tertiary (> 12 years). The correction techniques involve orthodontics, surgery or a combination of both. It is best practice to manage the position of the premaxilla pre-surgically with orthodontics. In that case, osteotomy of the premaxilla in combination with secondary alveolar bone grafting appears to be the most successful technique. This procedure should be carried out prior to the eruption of the permanent upper canines when the root has reached $\frac{3}{4}$ of its final size. This procedure, in most cases carried out when the child is 8-12 years old, results in fewer complications than primary, late secondary or tertiary closure.

Chapter three is an analysis of the outcome of the secondary alveolar bone grafting (SABG) procedure in combination with an osteotomy of the premaxilla. Complications related to the surgery and associated parameters were analyzed in 69 patients. There were three parameters that significantly correlated with complications: the timing of the SABG surgery, the preoperative (mal)position of the premaxilla and the preoperative bone quality around the cleft-related teeth. There were less complications if secondary alveolar bone grafting was done early. This means when the developmental stage of the root of the canine had developed beyond $\frac{3}{4}$, but definitively before eruption of the canine, or the lateral incisor, if present. Early SABG was done at a mean age of 10.7 years and late SABG at a mean age of 12.2 years. Patients over 12 years showed significantly more complications, resulting in more revision surgery. The preoperative malposition of the premaxilla also impacted the complication rate: more severe displacement of the premaxilla was associated with more complications. The same was true for the preoperative bone quality around the cleft-related teeth: more alveolar bone height loss led to more complications. It is concluded that optimizing the preoperative position of the premaxilla with orthodontics and timing of the surgery dependent on the root development of the teeth next to the cleft are important for achieving an outcome with little complications.


Chapter four deals with midfacial growth in 59 BCLP patients who underwent SABG surgery combined with osteotomy of the premaxilla. The BAURU Yardstick was used to assess the dental arch relationship in BCLP patients and allocate it to one of categories 1 (good results) to 5 (poor results). Also standardized lateral cephalograms were obtained during the treatment, pre-SAGB, directly post-SAGB, and the most long-term cephalogram available. From the cephalograms four angles were calculated: SNA, SNB, ANB and the upper incisor/SpP angle. The BAURU yardstick results were compared to results at children's hospitals in Goteborg, Nijmegen and Oslo. There were no significant differences in midfacial growth between these four centers. ANB and SNA angles decreased over time, indicating lag of midfacial growth in BCLP patients. A correlation was found between pre-operative ANB angle and the end-point BAURU-scores, indicating that in our patient population ANB angle can be used to predict long-term midfacial growth. If before surgery ANB-angle is below 6 degrees there is a 78% probability that there will be an indication for a Le Fort I osteotomy at the age of 18.

Chapter five is an analysis of the end result of the bone grafting procedure and the orthodontic treatment from a clinically relevant perspective. This chapter analyses the outcome by means of a newly proposed Dento-Maxillary Scoring System (DMSS). In this new scoring system Panoramic X-rays are used in combination with data from patient files and lateral cephalograms. The parameters scored in this scoring system are: interruption of the dental arch between both maxillary canines, incisor relationship, persisting oronasal fistulas, and the Bergland/Abyholm criteria. On average 7.6 (standard deviation 2.2 with a median of eight) on a scale of 1-10 was scored. The dento-maxillary scoring system was easy to use with already available patient data without the need of extra consultation. The Bergland/Abyholm score has a statistically significant relationship with the occurrence of an interrupted dental arch. Fistulas that develop or persist after closure of the alveolar cleft in patients with BCLP influence the dental result at the end of the second decade.

Chapter six presents some perspectives on the future of bone grafting. Until now autologous bone is used to graft the alveolar cleft in BCLP patients. There are disadvantages for this procedure such as donor site related morbidity and complications. In the Wilhelmina Children's Hospital, nowadays a bone substitute beta Tricalcium Phosphate is used for closure of unilateral clefts. New solutions are emerging for bone tissue engineering. With the use of multipotent stem cells (MSC's) it is possible to differentiate these stem cells towards bone. However, until now translating this technique from the laboratory into the clinic has not been successful. This chapter looks at bone formation in the defect using enchondral bone formation. The currently used source for MSC's is bone marrow. Other options for harvesting MSC-like cells, for example neural crest derived stem cells from craniomaxillofacial sources, like mesenchymal pulp stem cells from extracted teeth, are discussed.

Chapter seven contains a general discussion with the following conclusions :

- Timing of repair of BCLP should be based on the development of the root of the lateral incisor and/or the root of the canine which should not have developed more than $\frac{3}{4}$.
- Late secondary alveolar bone grafting is associated with more complications after surgery in comparison with early secondary alveolar bone grafting.
- Growth retardation in the present study after closure of lip, soft and hard palate, and closure of the bilateral alveolar cleft with a premaxilla osteotomy is comparable with other centers.
- There was a decrease in SNA and ANB angle value over time, indicating a delayed growth of the maxilla.
- A correlation between a lower pre-operative ANB angle and a worse end-point BAURU score was found.
- Alveolar bone grafting together with premaxilla osteotomy is not a clinically relevant midfacial growth inhibiting factor in patients with BCLP, but prospective studies with standardized treatment protocols are needed for definite confirmation.
- An ANB angle value of 6° or less gives a 78% change for a negative sagittal frontal overjet at the age of 18 and need for a Le Fort I osteotomy.
- A Dento-Maxillary Scoring System is proposed for screening the dento-maxillary treatment results of bilateral cleft lip and palate patients.
- Using the Dento-Maxillary Scoring System, our cleft center obtained an overall score of 7.6 (SD 2.2 with a median of 8).
- The occurrence of fistulas postoperatively is related to an interrupted dental arch.



CHAPTER 9

Nederlandse samenvatting

List of publications

Dankwoord

Curriculum Vitae

NEDERLANDSE SAMENVATTING

Een review van de bekende literatuur en de tot op heden behaalde resultaten in het UMC Utrecht

In **hoofdstuk twee** wordt het behandelprotocol van het schisisteam in het Wilhelmina Kinderziekenhuis (WKZ) UMC Utrecht middels een review vergeleken met de verschillende behandelopties die in de literatuur worden toegepast. Hieruit wordt een consensus gedestilleerd.

Hoofdstuk drie beschrijft retrospectief het behandelprotocol van het schisisteam in het WKZ. Op dit moment is het protocol: secondary alveolar bonegrafting (SABG), in combinatie met een osteotomie van de premaxilla tussen de leeftijd van acht en twaalf jaar. De langetermijnresultaten en de complicaties, alsmede de timing van de bone grafting aan de hand van de ontwikkeling van de radix van de cuspidaat worden in dit hoofdstuk beschreven en geanalyseerd.

GROEI, DENTO-MAXILLAIRE ASPECTEN EN DE TOEKOMST VAN AUTOLOGE BOTTRANSPLANTATIES

In **hoofdstuk vier** wordt de maxillofaciale groei van patiënten met een bilaterale schisis (BCLP) vergeleken met eerdere studies uit de literatuur. De BAURU Yardstick wordt gecombineerd met cefalometrische analyse, waarmee de groei van de maxilla wordt geanalyseerd en voorspeld. Tevens wordt onderzocht welke factoren van invloed kunnen zijn op de groei van de maxilla.

In **hoofdstuk vijf** worden de resultaten van SABG in combinatie met een osteotomie van de premaxilla geanalyseerd op dento-maxillair niveau. Middels een nieuw Dento-Maxillair Score Systeem (DMSS) wordt een ideale uitkomst bepaald, waarmee alle geïncludeerde patiënten worden gescoord. Het DMSS is een gemakkelijk te gebruiken scoringsmethode waarmee het dento-maxillaire eindresultaat beschreven kan worden.

In **hoofdstuk zes** wordt een review verricht naar de toekomst van bottransplantaties. Tot nu toe wordt vooral gebruik gemaakt van autologe bottransplantaten afkomstig van verschillende locaties in het lichaam. In de nabije toekomst zal het mogelijk zijn om middels ontwikkelde botsubstituten en/of het kweken van stamcellen botconstructen te maken in het laboratorium.

Hoofdstuk één introductie. In Nederland wordt ongeveer 1 op de 500 kinderen geboren met een schisis van de lip, het verhemelte, de kaak of een combinatie hiervan. Meestal betreft het een enkelzijdige schisis (een unilaterale schisis: UCLP), maar bij ongeveer 1 op de 5000 kinderen is er een schisis aan twee zijden (een bilaterale schisis: BCLP). Bilaterale schisispatiënten worden bij voorkeur behandeld in een tertiair centrum; een voorbeeld

hiervan is het Wilhelmina Kinderziekenhuis (WKZ). Dit ziekenhuis is onderdeel van het Universitair Medisch Centrum (UMC) Utrecht. In het WKZ worden patiënten met een schisis behandeld in een multidisciplinair team. Dit team bestaat uit experts van de vakgebieden gynaecologie, plastische chirurgie, kaakchirurgie, orthodontie, audiologie, KNO, logopedie, genetica, psychiatrie, tandheelkunde, ergotherapie en een lactatiedeskundige.

Een belangrijk aspect van de behandeling van patiënten met een bilaterale schisis is het goed positioneren van de premaxilla en het sluiten van de kaakschises. De bilaterale schisis veroorzaakt een zeer mobiele en alleen apicaal gefixeerde premaxilla. In deze thesis wordt de focus gelegd op dit onderdeel van de behandeling, het sluiten van de kaakschises en het goed repositioneren van de premaxilla tussen de leeftijd van 8-12 jaar.

De thesis bestaat uit:

- Review van de literatuur met betrekking tot het repositioneren van de premaxilla
- Een analyse van de secondary alveolar bonegrafting (SABG) procedure, in combinatie met een osteotomie van de premaxilla
- Een analyse van de groei van het middengezicht (maxilla) bij patiënten behandeld in het WKZ in vergelijking met de resultaten de behandelingen van patiënten uit Göteborg, Nijmegen en Oslo
- Een analyse van het eindresultaat van de secondary alveolar bonegrafting (SABG) procedure, in combinatie met een osteotomie van de premaxilla vanuit een klinisch relevant perspectief middels een nieuw Dento-Maxillaire Scorings Systeem
- De toekomst van bone grafting

Hoofdstuk twee is een review van de literatuur, met betrekking tot de positie van de premaxilla. Na analyse van de beschikbare literatuur werden er 16 relevante artikelen gevonden. De artikelen werden geïncludeerd in de review omdat er een beschrijving werd gemaakt van de timing van de bot-in-gnatho operatie, de techniek van de procedure, de complicaties, de chirurgische resultaten en de groei van de maxilla. In de artikelen worden verschillende methoden beschreven om de positie van de premaxilla te corrigeren. Dit kan worden gedaan op een vroege leeftijd: vroeg primair (< 8 jaar); tevens kan het worden gepland tussen de 8 en 12 jaar: vroeg- of laat secundair en als laatste, ouder dan 12 jaar: laat tertiair sluiten.

Er worden verschillende technieken beschreven om de positie te corrigeren namelijk orthodontisch, chirurgisch of een combinatie van beide. Het beste resultaat wordt bereikt wanneer de premaxilla pre-chirurgisch wordt gepositioneerd middels orthodontie, waarna een osteotomie wordt uitgevoerd in combinatie met een bottransplantaat. Deze procedure moet worden uitgevoerd voordat de blijvende cuspidaat doorbreekt in de schisis, als de radix van dit element voor $\frac{3}{4}$ is afgevormd. De procedure heeft plaats tussen de 8-12 jaar en laat minder complicaties zien dan vroeg primair, laat secundair of tertiair sluiten.

Hoofdstuk drie beschrijft een analyse van de resultaten van secondary alveolar bonegrafting (SABG) in combinatie met een osteotomie van de premaxilla. De complicaties in samenhang

met de chirurgische interventie werden geanalyseerd bij 69 patiënten. Er werden drie parameters gevonden die significant correleerden met het ontstaan van een complicatie: timing van de SABG procedure, de pre-operatieve (mal)positie van de premaxilla en de pre-operatieve botkwaliteit rond de elementen aansluitend aan de schises. Vroege SABG vond plaats op een mean leeftijd van 10.7 jaar en late SABG vond plaats op een mean leeftijd van 12.2 jaar. Bij patiënten die ouder waren dan 12 jaar, werden significant meer complicaties gezien en werd meer revisiechirurgie uitgevoerd. De preoperatieve malpositie van de premaxilla had ook invloed op het aantal complicaties: een meer uit positie staande premaxilla zorgde voor meer complicaties. Ditzelfde werd gezien bij de botkwaliteit rond de elementen, aangrenzend aan de schises: meer botverlies rond de elementen zorgde voor meer complicaties. Geconcludeerd werd dat een optimale preoperatieve positionering van de premaxilla middels orthodontie en een juiste timing van de ingreep aan de hand van de ontwikkeling van de radix van de cuspidaat belangrijk zijn om een goede uitkomst te behalen, met weinig kans op complicaties.

Hoofdstuk vier beschrijft de groei van het middegezicht (maxilla) bij 59 patiënten met een bilaterale schisis, die zijn behandeld middels secondary alveolar bonegrafting (SABG) en een osteotomie van de premaxilla. Het BAURU Yardstick score systeem werd gebruikt om gipsafdrukken van de tandenbogen te analyseren. De BAURU Yardstick is onderverdeeld in vijf categorieën waarbij 1 een goed resultaat en 5 een slecht resultaat is. Tevens werd er een cefalometrische analyse op laterale schedelfoto's (RSP) gedaan. Er werd gebruik gemaakt van de preoperatieve RSP, de direct postoperatieve RSP en de eind RSP. Er werden vier hoeken gemeten op deze opnamen namelijk: SNA, SNB, ANB en de hoek van de bovenincisieven ten opzichte van de bovenkaak.

Onze resultaten van de BAURU Yardstick analyse werden vergeleken met de resultaten uit de ziekenhuizen van Göteborg, Nijmegen en Oslo. Hierbij werden geen significante verschillen gevonden in groei tussen de verschillende centra.

Bij cefalometrische analyse werd over de tijd een afname gezien van de hoeken ANB en SNA; dit kan wijzen op een afname van de groei van het middegezicht. Er werd een correlatie gevonden tussen de preoperatieve ANB hoek en de eindpunt BAURU scores. Dit gaf een indicatie dat het mogelijk is de ANB hoek te gebruiken om de groei van het middegezicht op lange termijn te voorspellen. Wanneer er voor de chirurgie een ANB-hoek bestaat van kleiner dan 6 graden is er een 78% kans dat er op 18-jarige leeftijd een indicatie bestaat voor het verrichten van de Le Fort I osteotomie.

Hoofdstuk vijf analyseert het eindresultaat van de bottransplantatie en de orthodontische behandeling vanuit een klinisch relevant perspectief. De analyse wordt verricht middels een nieuw Dento-Maxillair ScoreSysteem (DMSS). Middels dit nieuwe scoringssysteem wordt er gebruik gemaakt van een combinatie van de X-OPT foto's, patiëntendata en laterale schedelfoto's. De verschillende onderdelen die worden gescoord in het scoresysteem zijn: onderbreking van de tandboog tussen de cuspidaten, frontrelatie, persisterende oronasale fistels en de Bergland/Abyholm criteria. De gemiddelde score was 7.6 (standaard deviatie

2.2 met een mediaan van acht) op een schaal van 1-10. Het DMSS is gemakkelijk te gebruiken ter analyse van reeds bestaande patiëntgegevens, zonder dat de patiënt hiervoor opnieuw naar het ziekenhuis moet komen. De Bergland/Abyholm score heeft een significante relatie met voorkomen van een onderbroken tandboog. Fistels die ontstaan of blijven bestaan na secondary alveolar bonegrafting beïnvloeden het eindresultaat op volwassen leeftijd.

Hoofdstuk zes bespreekt de toekomst van bottransplantaties. Tot op heden wordt er een autoloog bottransplantaat gebruikt om de kaakschises te sluiten bij patiënten met een bilaterale schisis. De nadelen van deze ingreep zijn donorlocatie, morbiditeit en complicaties. In het WKZ wordt bij patiënten met een unilaterale schisis gebruik gemaakt van een botsubstituut dat bestaat uit Bèta Tricalcium Fosfaat (β -TCP). Een andere mogelijkheid zou zijn om in het laboratorium bot te kweken uit multipotente stamcellen (MSC) en hiervan, eventueel in combinatie met een botsubstituut, een transplantaat te maken. Echter tot op heden is het nog niet goed gelukt om de overstap van het laboratorium te maken richting de kliniek. In dit hoofdstuk wordt geanalyseerd wat er bekend is over het gebruik van enchondrale botvorming om een botdefect op te vullen. Tot nu toe wordt er vooral gebruik gemaakt van MSC's uit het beenmerg. Een andere mogelijkheid zou kunnen zijn om cellen te oogsten uit craniofaciale bronnen zoals mesenchymale pulpastamcellen uit geëxtraheerde elementen.

Hoofdstuk zeven bevat de discussie van deze thesis.

De conclusies die getrokken worden zijn:

- Timing van de bottransplantatie, indien noodzakelijk in combinatie met een repositie van de premaxilla, moet worden gedaan aan de hand van de ontwikkeling van de wortel van de cuspidaat en indien aanwezig de laterale incisief
- Laat secundair sluiten van de kaakschisis met een bottransplantaat is geassocieerd met meer complicaties in vergelijking met vroeg secundair sluiten van de schisis
- De vertraging van de groei van het middengezicht, die in dit proefschrift wordt gezien, is vergelijkbaar met andere schisiscentra
- Er is een afname van de SNA en ANB hoek in tijd; dit impliceert een vertraging van de groei van het middengezicht
- Er werd een correlatie gevonden tussen een lage preoperatieve ANB hoek en een slechtere BAURU Yardstick aan het einde van de follow-up
- Alveolar bone grafting, in combinatie met een osteotomie van de premaxilla, is een klinisch niet relevante remmer van de groei van het middengezicht bij patiënten met een bilaterale schisis. Maar om hier zeker van te zijn moeten prospectieve studies met een gestandaardiseerd behandelprotocol worden verricht.
- Bij een ANB hoek van zes graden of minder is de kans op een negatieve sagittale relatie van de frontelementen 78%. Er bestaat hierdoor een indicatie voor een Le Fort I osteotomie op 18-jarige leeftijd.
- Er werd een DentoMaxillaire ScoringsSysteem ontwikkeld waarmee op eenvoudige wijze het dentomaxillaire eindresultaat kan worden beschreven

- Bij de behandeling van bilaterale schisispatiënten werd een score van 7.6 (SD 2.2 met een mediaan van 8) behaald, gemeten met het DentoMaxillaire ScoringsSysteem
- Fistels na het uitvoeren van SABG zijn gerelateerd aan een onderbroken tandboog aan het einde van de behandeling.

LIST OF PUBLICATIONS

Bittermann GKP, Janssen NG, van Leeuwen M, van Es RJJ

One-year volume stability of human facial defects filled with a β -tricalcium phosphate-hydroxyl apatite mixture (Atlantik®)

J Craniofac Surg. 2014 Mar;25(2):372-4

doi: 10.1097/SCS.0000000000000636

Poort LJ, Bittermann GKP, Böckmann RA, Hoebbers FJ, Houben R, Postma AA, Kessler PA

Does a change in bone mineral density occur in the mandible of Göttingen Minipigs after irradiation in correlation with radiation dose an implant surgery?

J Oral Maxillofac Surg. 2014 Nov;72(11):2149-56

doi: 10.1016/j.joms.2014.05.025.

Paes EC, Bittermann GKP, Bittermann D, Muradin MM, van Hogezaand R, Ety E, Mink van der Molen AB, Kon M, Breugem CC

Long-Term Results of Mandibular Distraction Osteogenesis with a Resorbable Device in Infants with Robin Sequence: Effects on Developing Molars and Mandibular Growth

Plast Reconstr Surg. 2016 Feb;137(2):375e-385e

doi: 10.1097/01.prs.0000475769.06773.86

Bittermann GKP, de Ruiter AP, Janssen NG, Bittermann AJN, van der Moelen AB, van Es RJJ, Rosenberg AJWP, Koole R

Management of the premaxilla in the treatment of bilateral cleft of lip and palate: what can the literature tell us?

Clin Oral Investig. 2016 Mar;20(2):207-17

doi: 10.1007/s00784-015-1589-y

Kappen IFPM, Bittermann D, Janssen L, Bittermann GKP, Boonacker C, Haverkamp S, de Wilde H, van der Heul M, Specken TF, Koole R, Kon M, Breugem CC, Mink van der Molen AB

Long-Term Follow-Up Study of Young Adults Treated for Unilateral Complete Cleft Lip, Alveolus, and Palate by a Treatment Protocol Including Two-Stage Palatoplasty: Speech Outcomes

Arch Plast Surg. 2017 May;44(3):202-209

doi: 10.5999/aps.2017.44.3.202

Kappen IFPM, Bittermann GKP, Bittermann D, Mink van der Molen AB, Shaw W, Breugem CC

Long-term follow-up study of patients with a unilateral complete cleft of lip, alveolus, and palate following the Utrecht treatment protocol: Dental arch relationships

J Craniomaxillofac Surg. 2017 May;45(5):649-654

doi: 10.1016/j.jcms.2017.01.028

Janssen NG, Schreurs R, Bittermann GKP, Borstlap WA, Koole R, Meijer GJ, Maal TJJ
A novel semi-automatic segmentation protocol for volumetric assessment of alveolar cleft grafting procedures

J Craniomaxillofac Surg. 2017 May;45(5):685-689

doi: 10.1016/j.jcms.2017.02.018

Kappen IFPM, Bittermann GKP, Schouten RM, Bittermann D, Eddy E, Koole R, Kon M, Mink van der Molen AB, Breugem CC

Long-term mid-facial growth of patients with a unilateral complete cleft of lip, alveolus and palate treated by two-stage palatoplasty: cephalometric analysis

Clin Oral Investig. 2017 Jun;21(5):1801-1810

doi: 10.1007/s00784-016-1949-2

Kruijt Spanjer EC, Bittermann GKP, van Hooijdonk IEM, Rosenberg AJWP, Gawlitta D

Taking the endochondral route to craniomaxillofacial bone regeneration: A logical approach?

J Craniomaxillofac Surg. 2017 Jul;45(7):1099-1106

doi: 10.1016/j.jcms.2017.03.025

Bittermann GKP, de Ruiter AP, Bittermann AJN, Mind van der Molen AB, van Es RJJ, Koole R, Rosenberg AJWP

Midfacial growth and dental arch relationships in bilateral cleft palate following secondary alveolar bone grafting and orthodontic intervention: Factors predicting a Le Fort I osteotomy at age 18

J Craniomaxillofac Surg. 2018 Oct;46(10):1764-1771

doi: 10.1016/j.jcms.2018.07.014

Kappen IFPM, Bittermann GKP, Stock NM, Mink van der Molen AB, Breugem CC, Swanenburg de Veye HFN

Quality of Life and Patient Satisfaction in Adults Treated for a Cleft Lip and Palate: A Qualitative Analysis

Cleft Palate Craniofac J. 2019 Oct;56(9):1171-1180

doi: 10.1177/1055665619843410

Longoni A, Umtomo L, van Hooijdonk IE, Bittermann GKP, Vetter VC, Kruijtspanjer EC, Ross J, Rosenberg AJWP, Gawlitta D

The chondrogenic differentiation potential of dental pulp stem cells

Eur Cell Mater 2020 Feb 21;39:121-135

doi: 10.22203/eCM.v039a08

Bittermann GKP, van Es RJJ, de Ruiter AP, Frank MH, Bittermann AJN, van der molen AB, Koole R, Rosenberg AJWP

Incidence of complications in secondary alveolar bone grafting of bilateral clefts with premaxillary osteotomy: a retrospective cohort study

Clin Oral Investig. 2020 Feb;24(2):915-925

doi: 10.1007/s00784-019-02977-y

Bittermann GKP, van Es RJJ, de Ruiter AP, Bittermann AJN, Koole R, Rosenberg AJWP

Retrospective analysis of clinical outcomes in bilateral cleft lip and palate patients after secondary alveolar bone grafting and premaxilla osteotomy, using a new dento-maxillary scoring system

J Craniomaxillofac Surg. 2020 Dec 15:51010-5182(20)30265-1

doi: 10.1016/j.jcms.2020.12.006

PRESENTATIES

- 2011 Presentatie Najaarsvergadering NVMKA eigen verricht onderzoek naar secundaire orbitabodem reconstructie
- 2014 Presentatie Najaarsvergadering NVMKA literatuur review secundair alveolar bonegrafting en premaxilla osteotomie bij bilaterale schisis
- 2014 Presentatie Najaarsvergadering NVSCA literatuur review secundair alveolar bonegrafting en premaxilla osteotomie bij bilaterale schisis
- 2016 Presentatie Najaarsvergadering NVMKA Chondrogene differentiatiecapaciteit van dentale pulpa stamcellen
- 2018 Presentatie Najaarsvergadering NVMKA Gezicht uitgroei en dentale relatie bij patiënten met een bilaterale schisis: Voorspellende factoren voor een Le Fort I osteotomie
- 2019 Presentatie Najaarsvergadering NVSCA De incidentie van complicaties bij patiënten met een bilaterale schisis
- 2020 Presentatie Najaarsvergadering NVSCA Het Dento-Maxillaire Score Systeem. Een nieuwe methode om het eindresultaat van de gnathoschisis reconstructie te beoordelen.

OVERIG

- 2015 BOOA Grant Chondrogene en osteogene differentiatiecapaciteit van dentale pulpa stamcellen (DPSC's)

DANKWOORD

Professor Rosenberg, Toine, dank je wel dat je mij onder je hoede hebt genomen en opnieuw een impuls aan mijn onderzoek hebt gegeven. Het waren niet altijd gemakkelijke discussies, maar doordat jij mij steeds motiveerde is het proefschrift nu af.

Professor Koole, u nam mij eerst aan voor het keuze coschap kaakchirurgie, daarna voor een promotieplek en daarna voor de opleiding. Het was een langdurig traject, dat nu uiteindelijk geleid heeft tot dit proefschrift, dank u wel.

Robert, dank je wel voor je begeleiding; die begon al tijdens mijn studie geneeskunde met de publicatie van mijn allereerste artikel en verder tot nu, met de afronding van mijn proefschrift. Dankzij jou is alles op papier gekomen zoals het er nu staat. Weekenden lang hebben we analyses gedaan en nachtenlang heb jij alles gecorrigeerd.

Ad, dank je wel! We hebben veel meegemaakt met elkaar, weekenden in de modellenkast, op zoek naar de juiste modellen, passend bij de patiënten uit mijn onderzoek. Meermaals analyses van data, dagenlang schrijven aan het review, in Birdaard, onder het genot van wijn, whisky en veel goed eten. Maar ook skiën met de familie, met de bijpassende culinaire en wellness heen- en terugreis in de rode slee. En natuurlijk onze gezamenlijke liefde voor mooie auto's, wat ons bracht naar Berlijn, in de Porsche, en terug via Autostadt Wolfsburg met veel culinaire en culturele hoogtepunten. En niet te vergeten onze maandelijkse bijeenkomsten op de Pel of in een restaurant, lekker eten en lang praten. Dank je wel voor al je hulp met het proefschrift maar ook je persoonlijke ondersteuning en advies, een waardevolle vriendschap!

Jan Abbink, in een helaas te korte periode heb jij mij veel geholpen. Ik verbaasde me keer op keer in jouw interesse en ongelooflijke drang om alles te willen weten. Je had alle literatuur uitgeprint en gelezen, stapels dik. Daarna stelde je tot in detail vragen over operaties, patiënten enzovoort. Helaas hebben we het niet kunnen afmaken, maar jouw bijdrage is groot en zeer waardevol voor mij geweest.

Geachte leden van de leescommissie, ik wil u bedanken voor de tijd en inspanning die u hebt gestoken in de beoordeling van mijn manuscript en in de oppositie tijdens de verdediging hiervan.

Professor Kessler, dank voor uw bijdrage aan mijn opleiding en ontwikkeling tot nu toe en in de toekomst.

Professor Mink van de Molen, beste Aebele, dank voor jouw hulp bij mijn artikelen, en ook dank voor je persoonlijke adviezen.

Nynke, hopelijk zijn we binnenkort weer directe collega's, ik leerde je kennen via mijn broer. Jij introduceerde me bij de kaakchirurgie in Maastricht en mede daardoor ben ik nu bijna klaar met mijn opleiding.

Lauretta, wat een leuke tijd was het toen ik semi-arts was in Maastricht; je leerde me de eerste kneepjes van het vak, daarna volgden vele borrels op congressen. Nu start ik binnenkort opnieuw in Maastricht en hoop ik heel veel van jou te leren. Dank je wel voor je vriendschap, deze betekent veel voor mij.

Joeri, als semi-arts in Maastricht leerde jij mij de eerste kneepjes van het vak. Jouw enthousiasme en tips zijn mij mijn hele opleiding bijgebleven. Dank je wel!

Elmer, als ouderejaars AIOS heb jij mij altijd direct betrokken bij de groep, ook toen ik nog niet in opleiding was, dank daarvoor. We hebben veel samen gesport, samen gegeten en samen geschreven. Daarna heb je ook nog je beste vriendin aan mij uitgeleend, dank je wel!

Thomas, ook jij als ouderejaars AIOS hebt me altijd betrokken bij de groep en me later, als stafid, onder je hoede genomen. Het was altijd erg gezellig, samen opereren, samen eten, dank voor je bijdrage aan mijn ontwikkeling.

Michael, wij zaten bij elkaar op de kamer, dan kwam er weinig van promoveren, maar wel van gezellig koffiedrinken en het uitwisselen van zeer uiteenlopende adviezen. En natuurlijk dank voor je hulp bij de statistische analyses.

Hendrik, jij leerde mij de eerste kneepjes van het vak, luisterde naar mijn presentaties en gaf gevraagd en ongevraagd advies, dank je wel hiervoor!

Ajit, als enige KNO-arts had jij kantoor op de afdeling kaakchirurgie, een goede keuze, dit maakte het gemakkelijk even langs te komen voor een kop koffie en wat advies.

Debby, dank je wel voor je introductie in het lab, dit verbreedde mijn wetenschappelijk skills en kennis, ik heb veel geleerd tijdens de 'bone meetings', helaas bleken de pulpacellen iets minder goed te gebruiken dan gehoopt.

Iris en Monique, dank voor jullie ondersteuning. Corrigeren, uitprinten, allemaal snel en goed geregeld, dank!

Nard, samen geiten opereren, samen poli, samen naar Nijmegen, dank je voor deze interrupties tijdens het promoveren.

Geachte collega's uit het Q-gebouw, **Florine, Daan, en Reilly**, we hebben veel lol gehad met elkaar tijdens het promoveren en tijdens onze onderzoeksbesprekingen op externe locaties. Het was soms wat minder productief, maar wel erg gezellig.

Stafleden **Silke, Marvick, Ellen**, dank voor het delen van jullie kennis en kunde als bijdrage aan mijn ontwikkeling als toekomstig kaakchirurg.

Beste heren en dame van de Maatschap Kaakchirurgie Breda, beste **Peter, Bert, Eelco, Jan, Erik, Gertjan, Hanneke en Jop**. Dank voor jullie bijdrage aan mijn opleiding. In Breda is waar je het vak echt leert en, heb ik de leukste tijd beleefd. Dank voor jullie gastvrijheid, bijdrage aan mijn ontwikkeling, en de mogelijkheid die jullie boden dit proefschrift te kunnen afmaken.

Isabelle, dank voor je hulp, we hebben toch een aantal publicaties samen kunnen schrijven, ik heb veel geleerd van je gedrevenheid!

(Oud) collega's AIOS kaakchirurgie, dank voor de goede samenwerking en de leuke borrels op de werkvloer!

Sjors, van overbuurman tot vriend en nu mijn paranimf. Skiën, varen, op stap met de mannen, wonen op de Karel Doormanlaan. Alweer bijna twee jaar geleden jouw promotie en nu eindelijk die van mij. Dank dat je me bijstaat, en dank voor jouw statistische adviezen.

José en Martin, lieve schoonouders, jullie support is zeer waardevol voor ons en heeft er mede voor gezorgd dat dit proefschrift is afgekomen. Ondersteuning is nooit een probleem, klussen, oppassen, gezellig eten, dank jullie wel!

Heleen en Gerrit, ook wel Ome Heleen en Tante Gerrit. Al sinds jaar en dag zijn jullie een onderdeel van ons gezin, altijd en overal, skiën, vakantie met de boot, verjaardagen, noem maar op. Mede dankzij jullie word ik kaakchirurg, waarvoor ik jullie heel erg dankbaar ben. Jullie hadden vertrouwen in mij en twijfelden nooit mij te ondersteunen, dat is erg lief van jullie!

Dieneke, zusje, dank je wel voor alle gezelligheid en adviezen!

Jorg, in 2006 kwamen wij, na wat obstakels, bij elkaar in de jaarclub. Dit heeft zich in de loop der jaren ontwikkeld tot een zeer goede vriendschap in goede en slechte tijden. Dank vriend, voor je adviezen, je goede en trouwe vriendschap en de gezellige tripjes en wonen op de Karel Doormanlaan.

Joost, je bent niet alleen mijn broer maar ook mijn beste vriend, en nu mijn paranimf; dank je wel voor je ondersteuning tijdens dit langdurige traject. Je hebt me veel geholpen bij het schrijven van dit proefschrift.

Lietje en Dirk, lieve mama en papa, dank jullie wel voor jullie onvoorwaardelijke steun en vertrouwen; dankzij jullie motivatie en sturing in het leven heb ik dit weten te bereiken, ik hou van jullie.

Barbara, mijn lieve vriendin, ontmoet op de afdeling kaakchirurgie. Wij hebben niet alleen dezelfde passie voor het vak, maar ook dezelfde passie voor het leven, samen op vakantie, samen duiken, samen skiën. Nu hebben we twee lieve kinderen en gaan we op naar het volgende avontuur in het zuiden des lands, ik hou van je!

Lieve Barbara, Diederik en Tesse, ik hou van jullie.

CURRICULUM VITAE

Koen (Gerhard Koendert Pieter) Bittermann was born August 19th 1987 in Giessenburg, The Netherlands is engaged with Barbara Muller and has two kids Diederik and Tesse. During time at elementary school and secondary school an interest in going to study medicine was gained. In his sparetime he accompanied a family friend, who was a veterinarian, to work. Ultimately the decision was made for a study medicine in Maastricht. He graduated from the secondary school 'Merewade College Gorinchem VWO+' in 2006. And after the numerus clausus was passed he started his study medicine in Maastricht in 2006 and completed it in 2013. In the same year he also became a member of the student association 'StudentenVereniging Circumflex' in Maastricht. In 2009-2010 he was a board member as a commissioner for internal affairs and vice president.



During his medical study interest in the oral and maxillofacial surgery grew potentially, resulting in an internship at the Oral and Maxillofacial Surgery department at the UMC Utrecht in 2010, and later on also at the Maastricht University Medical Center in 2012-2013. In this final year Koen did research in the field of Maxillofacial Oncology under supervision of Professor Doctor P Kessler and Doctor LM Poort.

After graduation Koen became a PhD-Student at the department of Oral and Maxillofacial Surgery in the UMC Utrecht on the subject of patients with Bilateral Cleft Lip and Palate, under supervision of Professor Doctor R Koole, Professor Doctor AJWP Rosenberg, Doctor RJJ van Es and Doctor AP de Ruiter. This PhD-study was interrupted between 2015 and 2017 by the study dentistry at the Radboud University in Nijmegen. In 2018 he started his residency at the department of Oral and Maxillofacial Surgery at the Utrecht Medical Center (head: Professor doctor AJPW Rosenberg).

In his spare time Koen enjoys sailing, windsurfing, cycling, running, diving and skiing, and spending time with his family and friends.